

FALL 2022 | VOLUME 99, ISSUE 1

tda

JOURNAL

of the **TENNESSEE DENTAL ASSOCIATION**

TNDENTALASSOCIATION.COM

FIVE GENERATIONS OF DENTISTS

IN VIRGINIA, KENTUCKY
AND TENNESSEE

See Page 14



tda
JOURNAL
of the **TENNESSEE DENTAL ASSOCIATION**

CONTENTS

Editorial	04
Association News & Announcements	20
Continuing Education	26
Case Reports	53
Classified Ads	60

ADA C.E.R.P.[®] | Continuing Education
Recognition Program

The TDA is an ADA CERP provider (May 2021 – June 2024)
ADA CERP is a service of the American Dental Association to assist dental professionals in identifying quality providers of continuing education. ADA CERP does not approve or endorse individual courses or instructors, nor does it imply acceptance of credit hours by boards of dentistry. Concerns or complaints about a CE provider may be directed to the provider or to ADA CERP at ada.org/cerp.

Earn up to
50,000
bonus points
in the first year.¹

A \$500 value!



Reward your practice with the ADA® Visa® Business Rewards Card.

You can earn points faster where your practice spends the most – dental supplies. Earn from Benco, Schein, Patterson, TDSC and more!²

Additional earning and benefits:

- **5X POINTS** on ADA, co-endorsing state society, and select ADA Member Advantage endorsed provider purchases³
- **2X POINTS** at dental supply providers²
- **1X POINT** everywhere else Visa is accepted⁴
- **No limit** on the total points you can earn



Redeem your points for travel, merchandise, cash back in the form of statement credit and more.

All that plus:

- **NO** annual fee⁵
- **NO** foreign transaction fee⁵

Apply today at adavisa.com/37383

Rewards points are earned on eligible net purchases. Net purchases are purchases minus credits and returns. Accounts must be open and in good standing to earn and redeem rewards and benefits. Not all transactions are eligible to earn rewards, such as Advances, Balance Transfers, and Convenience Checks. Purchases qualify for Points based on how merchants choose to classify their business and we reserve the right to determine which purchases qualify. See your Cardmember Agreement for details. Points will expire five years from the end of the calendar quarter in which they were earned.

1. Earn up to an additional 50,000 bonus points in the first 365 days after account opening. Accounts will earn 1 bonus point in addition to the standard amount earned for each \$1 of eligible net purchases, up to 50,000 bonus points. Additional bonus points are only earned on purchases made using the Authorized Officer's Card. The Authorized Officer's Card is the card assigned to the initial applicant of the Account and would not include cards used by authorized employees. These bonus points will be awarded on your monthly billing statement. This offer may not be combined with any other bonus offer.
2. U.S. Bank cannot control how merchants choose to classify their business and reserves the right to determine which purchases qualify.
3. You will earn four (4) additional Points above base earn (for a total of 5 points) for every \$1 in eligible Net Purchases. In order to qualify for the (4) additional points on ADA purchases, the purchases must be from designated ADA Member Advantage endorsed providers, as determined by the provider. Some restrictions apply.
4. Reward points are earned with your ADA Visa credit card. Refer to your Program Rules at adavisa.com/faqs for additional information. Some restrictions apply.
5. The APR may vary and as of 3/22/2022, the variable APR for Purchases and Balance Transfers is 10.24% - 22.24% based on your creditworthiness. The variable APR for Cash Advances is 26.24%. Cash Advance fee: 5% of each advance amount, \$10 minimum. Convenience Check fee: 3% of each check amount, \$5 minimum. Cash Equivalent fee: 5% of each cash amount, \$20 minimum. Balance Transfer fee: 3% of each transfer amount, \$5 minimum. There is a \$2 minimum interest charge where interest is due. The annual fee is \$0. Foreign Transaction fee: None. We may change APRs, fees, and other Account terms in the future based on your experience with U.S. Bank National Association and its affiliates as provided under the Cardmember Agreement and applicable law.

ADA Member AdvantageSM is a service mark of the American Dental Association. ADA Member Advantage is a program brought to you by ADA Business Enterprises, Inc. (ADABE), a wholly owned subsidiary of the American Dental Association. ADA is a registered trademark of the American Dental Association.

The creditor and issuer of this card is U.S. Bank National Association, pursuant to a license from Visa U.S.A. Inc.

©2022 U.S. Bank

The Journal of Tennessee Dental Association, FORGING TOWARDS THE FUTURE!

The timing of the Tennessee State Dental Journal resuming is befitting to essentially the transition of the COVID-19 pandemic to an endemic, as slowly but surely life is recovering back to normal, albeit the "new-normal." The *Journal of the Tennessee Dental Association*, a part of the tri-partite affiliation with the American Dental Association, was on hiatus since late 2019 as it suffered a dual setback from the passing of its esteemed editor Dr. H. Clifton Simmons III in early 2019 and COVID-19 in early 2020.

Dr. Simmons led his life dedicated to dentistry. The many accolades, achievements, and lives he touched and transformed are difficult to put on a single page. A recipient of 13 Golden Pen awards during his tenure as an Editor of the TDA Journal from 2002-2018, he was also honored with the Jack Wells Memorial Dedication to Dentistry Award, the highest award given by the TDA. After graduating from UTHSC- College of Dentistry in 1977, he practiced in Nashville since 1978 and taught restorative dentistry at UTHSC College of Dentistry from 2009. He rose to the office of President in multiple organizations and was also the past President of the Tennessee Dental Association and of the American Association of Dental Editors and Journalists. Dr. Simmons was an accomplished editor receiving many awards and holding numerous editorial appointments along with the Journal of the TDA. The TDA Journal misses his immense knowledge and editorial expertise in bringing the Journal to the dental community of Tennessee.

It is remarkable to note that the *Journal of Tennessee Dental Association* has been in publication for over a century, being first published in 1919 under the editorship of Dr. Oren Oliver. The Journal has been through significant developments during this time. Between 1955 and 1974, Dr. Thomas Armstrong changed the format of the publication to a more modern style, for which the journal received an Honorable Mention Award for Improvement from the International College of Dentists.

Although the TDA Journal was on a brief hiatus, the exceptional team at the Tennessee Dental Association regularly published the TDA News. These newsletters keep the dental community abreast of the latest technical advances and the ever-changing guidelines of our "new normal" dental practice, not a small feat in the chaotic and unstable COVID-19 pandemic. *TDA News* has been with all dental professionals every step of the way as the practitioners juggled through many of challenges involving newer policies, procedures, patient backlogs, staff turnover and ensuring that oral health needs were met in addition to overall health.

As the TDA Journal comes back to the dental family of Tennessee, I am incredibly grateful to Dr. Jack Gotcher, Dean Dr. James Ragain, Dr. Paul Cullum, Dr. Zack Carden and the TDA Board of Trustees who have given me an opportunity to play a small part in its publication. Bringing the Scientific content that stands the perusal of peers is the keystone of this publication.

Tennessee is blessed with two established dental schools UTHSC, College of dentistry and Meharry Medical College, School of dentistry and one upcoming dental school, Lincoln memorial university, College of Dental Medicine. The faculty of these schools are frequently engaged in research, treat unusual cases, or are exposed to newer materials, technical or procedural advances that, when brought forth, will benefit the dental community. There are more than 3000 licensed dental practitioners in Tennessee with varying degrees of experience. We welcome their pearls of wisdom in the form of letters, opinions, critiques, and praises, on the whole nine yards of dentistry. As can be seen in this issue, the Journal content is divided into editorials, continuing education articles and case reports, thus covering greater expanse of scientific repertoire and making it relevant to a diverse dental community. As an upcoming new feature, we request the various residency directors to call upon their residents to submit abstracts of relevant papers published in their field in the past year, to bring about an awareness in the advances taking forth in the numerous dental specialties.

The researchers and dental professionals who submit their work for publication and the peers who review them are the two pillars supporting this journal; Without either of whom, the journal would be a distant dream. To sum it all up, the Journal of Tennessee Dental Association is your journal and only your participation will help it forge successfully into the future!



Vrushali Abhyankar, BDS, MDS, MS
Scientific Editor –
Journal of Tennessee Dental Association

Put the pliers down, let the pros do their job.

Some brokers just send you the candidate
and leave all the heavy work to you -
Would your patient pull their own teeth?

Trust your practice sale to an *experienced
full service broker* who has had hundreds
of practice sales.

(877) 365-6786 • choicetransitions.com



EASTERN TENNESSEE
Jay Lowery x221

WESTERN TENNESSEE
Fred Bacon, DDS x220

Considering selling to a DSO? Don't, until you read this.

“

Choice walked me through the process, presented the best offers, and made the experience much less stressful by handling all the negotiations. In the end, I received more for my practice than I ever expected. The best part is that Choice provided all the consultation and services to me without charging any fees! If you are considering selling to a DSO, I highly recommend you contact Choice instead of directly contacting the DSOs.

”

Commission free. DSO Choice.

Call 774-DSO-INFO • choicetransitions.com



Dental Care in Tennessee: Workforce Development & Rural Outreach

Founded in 1878, the College of Dentistry (COD) at the University of Tennessee Health Science Center (UTHSC) has a proud legacy; currently, a vibrant statewide portfolio, is the 3rd oldest public College of Dentistry in the nation, and has a bright future. Originally located in Nashville, the COD moved to Memphis in 1911 to enable the expansion of its programs. Today, our college is poised for further expansion, with a new \$46 million Delta Dental state-of-the-art building coming online in early 2023. This building will be a dynamic venue for learning, discovery, and clinical dental care.

// WHILE WE ARE PROUD TO CALL MEMPHIS 'OUR HOME,' TENNESSEE IS TRULY OUR CAMPUS. WE HAVE CLINICAL-EDUCATIONAL SITES ALSO IN NASHVILLE, UNION CITY, BRISTOL, AND CHATTANOOGA.

As you might expect, as the state's only public dental college we also serve as one of the public dental schools for the State of Arkansas as well. Entrances for students are highly competitive: we typically have in excess of 2,200 applications for 110 placements for our Doctor of Dental Surgery (DDS) degree. We also support a Bachelor of Science degree for dental hygienists, with 36 students per class. Our students train in vibrant clinical settings, including our busy dental practice in the Dunn building in Memphis where some 60,000 people annually receive exemplary dental care.

While we are proud to call Memphis 'our home,' Tennessee is truly our campus. We have clinical-educational sites also in Nashville, Union City, Bristol, and Chattanooga – with more new sites in the works (see below). Our faculty are representative of both general dentistry and subspecialties, and they publish approximately 100 scholarly articles annually. As expected of an academic institution, our faculty are also prominent in state and national dental organizations and societies. They take particular joy in being consummate educators and exemplary role models for our trainees.

Our faculty and our COD are highly supported by our COD

Alumni Association, with members among the most distinguished dental practitioners in the nation. The generosity of our alumni with their advice, educational support, giving, and ever-increasing philanthropy (COD fundraising reached an all-time high in 2022) is an immense source of motivation for all of us at UTHSC and is truly appreciated – always.

We are proud of our work and our noble mission. And yet, it is not enough. The dental needs of Tennesseans still go unmet, especially in rural Tennessee. We note that despite our concentration on training dentists and dental hygienists, our state still falls below the national rate of 60 dentists per 100,000 population – in fact, we come in at less than 50 dentists per 100,000 Tennesseans. But these figures don't portray the complete story: We have pronounced dentist shortages in rural Tennessee regions. Indeed, it is estimated that there are 4 dentists per 100,000 population in rural Appalachia.

What is the remedy to this vexing situation? Working with our colleagues at Meharry Medical College School of Dentistry and with the Tennessee Department of Health, we are launching the Healthy Smiles Initiative (HSI), an ambitious new statewide program to increase the number of dental students and to stimulate retention and relocation of our graduating dentists into practices in rural Tennessee. We are grateful to our distinguished alumnus, Dr. Phillip Wenk, for spearheading this initiative alongside our COD Dean (and alumnus of class of 1984) Dr. James Ragain. We are especially grateful to Tennessee Department of Health, our legislative leaders, and Governor Lee for supporting this vital initiative to increase the amount and distribution of Tennessee's future dental workforce. As just one example of this work and its potential, we are collaborating with East Tennessee State University, Ballad Health, and the dedicated community leadership of Kingsport to expand dental education in East Tennessee, ultimately with an eye to 'grow and retain our own.' Basic components of HSI are listed in Table 1.

Looking back on all our recent accomplishments and over the last 144+ years of serving the great State of Tennessee, our college is also looking forward with great enthusiasm to ensure that the next 144+ years is even better than the last. Then, now, and into the future, we remain diligently focused on our noble mission to improve Tennesseans' oral and overall health.

TABLE 1

Tennessee's Healthy Smiles Initiative – a UTHSC College of Dentistry led statewide collaboration

CORE COMPONENTS

- Incrementally increase UTHSC dental (from 100 to 130) and dental hygiene (from 30 to 50) class sizes
- Corresponding attention to retention and recruitment of College of Dentistry faculty
- Enhanced recruitment of students from rural counties in Tennessee
- Expansion of clinical training and rotations in rural communities across the great state of Tennessee
- Expand College of Dentistry's primary oral health care residencies
- Expand Functions Dental Auxiliary (EFDA) courses
- Assist with incentive programs to attract graduates to practice in underserved areas



PETER F. BUCKLEY, MD



JAMES RAGAIN, DDS, MS, PHD

Admissions at the University of Tennessee College of Dentistry

PART 2: A VIEW FROM THE INSIDE

Dayna D. Myers, RDH, BBA, MDH | J. Stansill Covington III, DDS, MS

INTRODUCTION

Professional school admissions have often been a mysterious process for those not involved. The realities of high demand and low supply result in many more denial letters than letters of acceptance. The purpose of this paper is to examine professional school admissions from the “inside.”

CHARACTERISTICS OF THE ENTERING CLASS

Currently, the maximum dental school entering class size is 110 students. This number is due to the UTHSC-COD dental technique laboratory having 110 workstations. The approximate breakdown of a typical entering class is:

65-70% Tennesseans

21% Arkansans¹

12-15% Out-of-state (or additional Arkansans)

We anticipate a gradual increase in class size over the next few years if approved by the American Dental Association’s Council on Dental Accreditation.

THE TENNESSEE APPLICANT POOL

Competition for admission to dental school is intense. In a prior paper, the increase in applications over the past ten years was noted.² Typically the application pool, taken as a whole, is comprised of at least 15, and occasionally 20, fully qualified applications for each position in the class. Table 1 shows the number of Tennessee applicants for the past 7 years along with their mean grade point average (GPA) and Dental Admissions Test (DAT) composite score.

THE ADMISSIONS COMMITTEE

The voting members of our Admissions Committee are dentists employed by UTHSC-COD - either full-time or part-time. Other schools have other types of professionals on their committees but we do not. All voting members have applied to dental school at some time and have been applicants, thus we feel there is empathy among committee members for the process. The two authors (Chair of the Committee and Director of Admissions Administration) do not vote on any applicant. The Admissions Committee typically has 21 voting members and the term of office is three consecutive years. Each person on the committee is elected by the faculty to serve a three-year term with at least one year between terms. The Committee begins each year with an early summer organizational meeting to review and discuss criteria we believe the ideal dental student should possess. After this

meeting, the interview period begins and runs from early August through December (or later if necessary).

THE APPLICATION PROCESS

Most colleges of dentistry, including the UTHSC-COD, use the American Dental Education Association’s “Associated American Dental Schools Application Service” (AADSAS). In this system, the application period for our school opens on June 1. The applicant applies one year before the anticipated matriculation. Our application “window” is open for four months (June 1 to September 30) and applications submitted to AADSAS after September 30 are not accepted.

Once a student submits their application material, it takes three to four weeks for AADSAS to verify, process, and assemble the information. Thus, typically the first batch of applications arrives in late June. Newly verified applications are transmitted electronically most every day until approximately November.

APPLICANT FLOW THROUGH THE SYSTEM

Figure 1 is a schematic outline of how different types of applicants move through the system. An offer of acceptance is a result of three levels of review. A description of the different parts of Figure 1 follows.

THE INTERVIEW

Everyone accepted into dental school must be interviewed in some fashion. With the recent insertion of Covid-19 into everyone’s lives, modifications to the interview process have been made.

INTERVIEWS DURING “NON-COVID” TIMES:

Our interview day is a low-key affair in which the applicants are exposed to our students, faculty, and facilities in addition to the interview itself. The process takes approximately five to six hours. Most interview days include an invitation for the applicant to bring along a family member (we are one of the few schools in the country to extend this invitation). The interview day schedule is such that we can only interview approximately 12 – 15 % of our applicants in any given year. It is reasonable for the applicant to think if invited for an interview, the Admissions Committee has found no significant fault in their application.

Disclaimer: This guest editorial is comprised of events and incidents the authors have personally seen within the past decade while advising students applying to the UTHSC College of Dentistry. Nothing in the editorial to follow is to be construed as the policy of the University of Tennessee Health Science Center College of Dentistry (UTHSC-COD) nor does it refer to any specific applicant.

INTERVIEWS DURING “COVID” TIMES:

With the campus being restricted to visitors of any type, the Admissions Committee developed a remote interview process that, while not perfect, appears adequate. The candidate is invited to select from a range of interview times and the Zoom³ program is utilized. The interviews, which include two members of the Admissions Committee, last between 20 to 30 minutes and follow the same general pattern of questions about experiences during “non-Covid” times. Immediately following the interview, the two committee members rate the interview separately and confidentially.

It may be surprising but the interview itself, either Covid or non-Covid, is not especially important to the overall admission process. The feeling among the Admissions Committee members is “Should a 20-minute interview derail three- or four years’ worth of effort it took to get the interview?” However, during the interview, we are examining the areas of academic preparation, investigation of the profession, and verbal adequacy (communication skills).

INTERVIEWS GOING FORWARD:

The online interview process, while not perfect, does have some advantages. These include no travel expenses, no time away from campus or other activities, and being able to select from a range of scheduled offerings. The Admissions Committee anticipates that an applicant will be offered both in-person and online interview options going forward. Since we can only interview a fraction of our applicants, we only interview an applicant once. When an applicant does not gain admission and reapplies, the Admissions Committee will use our notes from the original interview along with the updated application to re-evaluate the applicant.

THE SELECTION PROCESS

The Admissions Committee, in general, thinks the following are important qualities for an applicant:

- Full-time course loads at a four-year institution. My grade point average is around 3.50...DAT around 20 with no subsection scores below 18
- Very few, or no “Ws” (withdrawals) on the transcript. A transcript peppered with “Ws” makes it look like when the going got tough, the applicant withdrew
- No “cherry-picking” – going to a community college each summer to take organic chemistry or physics when their home school offers everything they need
- Having a good idea of what a day in the life of a general dental practice is like
- Regular, continuous involvement in the life of their community

As the application cycle continues into the fall, typically the Committee has several tentative selection meetings. Figure 1 shows the basic selection process. In the first selection meeting, we consider only previously interviewed re-applicants. Those moving forward from the first selection

meeting will be compared with newly interviewed applicants in a series of selection meetings that follow and typically end just before Thanksgiving. By agreement with AADSAS, we cannot transmit any acceptances to applicants until the first business day in December.

After initial notification of acceptance, the newly accepted applicant is given a fixed time to make their seat deposit and complete a variety of administrative tasks (background check, sending final transcripts, proof of immunization, etc.).

POST-SELECTION PERIOD

All applicants selected in December must be given a 30-day “no contact” period in which to consider their offer(s). In January, the newly selected applicants are examined to see if they have followed through on their pre-matriculation tasks. Those not-completing the tasks are contacted. If the newly accepted applicant declares they are attending another school, their offer of acceptance is rescinded and an applicant from the alternate list replaces them.

During the “no contact” period, alternate lists are composed. There are three lists: Tennessee, Arkansas⁴, and Out-of-state. By policy, we neither disclose how long the waitlist is nor where an applicant is on the list. Our feeling is that this does little more than stir up anxiety. For instance, if we told an applicant he/she was second on the waiting list, the applicant could easily be waiting for a call that never comes.

ADVISING AND INTERACTING WITH APPLICANTS

In the course of advising potential applicants, several themes commonly emerge and are outlined below.

“Do you fully understand what we are saying?”

If we learned something very early on, it was to be certain that the applicant fully understood what we were saying as opposed to their interpretation. Often an applicant asks the very reasonable question: “What would make me more competitive?” We will look at their academic record and maybe make some recommendations such as “If you take these courses and make good grades, you will be more competitive.”

What we found out was the applicant thought they “heard:” “If I take these courses and make good grades, I will get in.”

Another variant on this is in the realm of DAT scores. An applicant asks one of us if retaking the DAT will help their application. One of us might tell them a score of at least 19 is what it takes to be competitive....and they often “hear” “if I make a 19, I will get in.”

“I need six apples for a pie.”

This fictitious request is something like what the task the Admissions Committee has before us each year. I have been asked to go to the market and get six apples for a pie. At the market, there are hundreds and hundreds of apples. I look over the selection, choose six to buy, and go home.

My spouse asks me “Why did you buy those six apples?”
 My reply: “What is wrong with these six?”
 Spouse: “Well... nothing... just wanted to know why these are so special.”
 Me: “I chose the best I could.”

We feel that this analogy is useful. We are looking for 110 “apples” and we have over 1500 nice “apples” from which to choose. All we can assure the applicants (and everyone else concerned) is that we take the tasks before us very seriously and do the very best that we can. What follows are the things we hear from applicants and others.

THINGS WE HEAR FROM APPLICANTS OR HAVE SEEN IN APPLICATIONS:

“My grades (or scores) are not a true reflection of my ability.”

This is extremely common. So...what are you telling us...you weren't trying? Most applicants with low grades or scores say this. We tend to disagree. Your record is your record. Also, if we accept you, what do you suggest we say to the student with higher grades/scores whom we didn't accept?

“There is much more to me than my grades (scores).”

Yes...like the above, we know that. Again this is often used by applicants. However, we are trying to make an academic/intellectual decision. We are looking for an applicant whom we feel can withstand the rigors of four years of dental school and are not looking for a talk show host.

“I am on your waitlist and just got accepted to XYZ Dental School – what should I do?”

Our advice, 100% of the time, is to take the sure thing. If the call is an attempt by the applicant to entice us to move him/her up the waitlist, it won't be successful.

“My grades are low because I was on the football (or other) team.”

Collegiate sports instills many excellent characteristics in participants: time management, the ability to stick to a schedule, and perseverance. The thinking of the applicant is that we should make some grade point average allowance for sports. However, since our campus doesn't have any intercollegiate sports teams, academics will have to play an important part in our decision.

“Just give me a chance (and admit me).”

By applying for admission, you are getting your chance. As far as admitting someone by “giving them a chance,” we would thereby be denying another student's opportunity. Our pre-clinical laboratory has 110 workstations. Unlike (for instance) a law school where an additional row of seats could be added to a lecture hall, 110 new students per class is the current absolute limit.

Furthermore, when a student is dismissed for academic reasons, the losses are many:

- The student loses and can't be replaced in the curriculum
- The community in which the student was going to practice has now lost their practitioner
- The applicant who did not get in and didn't get a chance also loses
- The college loses several semesters of tuition

What is the lowest GPA / DAT you admitted last year?

An applicant asking this question is aiming at the wrong goal.

“I am pretty sure AADSAS made a mistake calculating my GPA”

Well...probably not. The AADSAS calculated GPA includes all attempts at a course (even if the undergraduate school does not). All activity courses and some fine arts courses are also omitted. Thus the AADSAS calculated GPA can easily be quite different (and lower) from the one the student sees.

“I will get in sooner or later if I keep applying.”

The Admissions Committee notes and appreciates persistence. However, many times the applicant seems to visualize a decreasing pool of applicants – increasing their chance of success each admissions cycle. When in fact, each year a wave of first-time applicants appears to renew the level of competition.

“When I was on a mission trip, I extracted a bunch of teeth!”

If an applicant is trying to make the Committee angry, this is the quickest way to do it. A mission trip to a third-world country should be delivering first-world care. Allowing unlicensed participants to deliver direct care is immoral.

“I already know how to take x-rays!”

We trust that your application reflects that you are a properly licensed/registered dental assistant or dental hygienist and are allowed to produce radiographs.

“I can't wait to “give back” to my community!”

Why doesn't your application reflect this desire?

“My goal is to open and operate a free clinic for my community.”

While many practitioners deliver free dental care in a variety of ways, more than anything this statement shows a basic lack of understanding of the economics of a dental practice.

"I was born with a very strong competitive nature..."
"I have always been a fighter and never give up..."
"Shakespeare once wrote..."
"Webster's dictionary defines ..."

These are snippets from personal statements. Many applicants feel the need to wax eloquently in their personal statements. This is not the statement's purpose. The purpose is to tell your story about your pursuit of dentistry as a profession...and longer is not better.

***"Arrgh! My Phone is Dead!...or I am
Otherwise out-of-touch"***

An applicant selected for admission cannot lose their slot by missing a phone call or being out of touch. The Committee will use every means of communication available to contact the applicant.

***"I was on the alternate list last year,
will I get in this year?"***

The competition is renewed each year. Previous alternate list members are closely examined by the Committee, but acceptance is not assured.

"What will make my application stand out?"

This is, by far, the most common question by an applicant... and the answer to that most common question is good grades, good scores, abundant shadowing, and consistent activity in your community.

COMMENTS HEARD FROM ALUMNI, DENTAL MENTORS, AND PARENTS:

Virtually every applicant has someone "in their corner" as their advocate. Each advocate attempts to provide sage advice and arguments as to why the applicant should gain admission. Some of the arguments offered are:

***"You need to admit (my child) because I need to hand
over my practice."***

This is perhaps the weakest admission argument of all.

"I just KNOW they will succeed in dental school."

Well, we know you truly believe that, but we get a surprise or two every year.

"Grades are not that important."

When someone with a 3.90 GPA says this, we'll start listening.

"I have been mentoring (student) for three years..."
"I can't understand why (student) hasn't been admitted."

There are three likely reasons for this:

1. The mentor has no idea what the student's grades are and assumes they are competitive or,
2. The mentor is not aware of what it takes to be competitive in today's environment, or
3. The student has been less than forthcoming about their grades. "Oh...I said my GPA is 3.80??? ...I really meant 2.80!"

Parent calling us: "Should my child take this course or that course...?"

Parent calling us: "I want my child to go to dental school."

It is always a red flag to us when a parent calls on behalf of the adult child. Recently we suggested that the child call so we could speak directly with him/her and the parent replied: "(Child) doesn't like to talk on the phone."

"What's my status?"

This common question, usually in the form of a telephone call, is not necessary. An applicant's status is correct on the AADSAS system 100% of the time. Unfortunately, we feel that this call is an excuse to stay in touch (aka – "stay on their radar"). Some applicants feel, or have been told, to call frequently for almost any reason. This call will be fruitless, and possibly counterproductive, as no one speaking to an applicant vote for admission. The Dean of Admissions and the Director of Admissions manage the applicant pool and data but only members of the Admissions Committee vote.

***"I heard that someone with a 2.50 GPA
and a DAT of 16 got in."***

We hear things like that too, but this is unlikely.

***"I know someone with lower grades and
scores who got in."***

This is certainly possible. While grades and scores are quite important, several other criteria need to be in place for an acceptance to be offered.

FROM LETTERS OF RECOMMENDATION AND OTHER COMMUNICATIONS:

***"(Applicant) is a great person from a great family,
...and will be a great asset to the profession and has
great grades..."***

We know the applicant's grades and scores and we assume an applicant is a good person. This letter is usually too generic to be of much help. In general, we like to hear from professors.

“Last week when I was eating lunch with the governor/mayor/senator...”

When a third party, even one with only the best of intentions, tries to influence The Committee, this will almost certainly end badly. Many on the Committee remember a time when you would get in if you knew the “right” people.

Also, our Communication Policy is we only communicate with the applicant about the applicant.

MASTER’S DEGREES:

Lately, a new wrinkle has arisen on the admissions landscape – a new type of “Master’s” degree. Until fairly recently a typical Master’s degree was normally two years in length and represented concentrated study in a specific discipline (e.g. – microbiology, biochemistry) 4. Admission to these programs commonly is based on standardized testing such as the Graduate Record Examination or the Graduate Management Admission Test.

Lately, “Master’s” degrees have sprung up at many schools to take advantage of the large pool of applicants who did not get admitted into medical or dental school. These new programs often require nothing more than an MCAT or DAT for entry with either no or a very low threshold score. The

“publicity” for these programs “guarantees” a “Master’s” degree in one year...just in time for the next admissions cycle.

So...what’s the problem? In the view of some on the Admissions Committee, some of the schools offering these degrees either don’t have a graduate school or admission to these degree programs are held to a different (read: lower) standard. Besides, these degrees are “Masters’ of Biomedical Sciences” – not a Master of any specific discipline. The coursework consists of a year of upper-level science courses. There is nothing wrong with that, but the grading scale in graduate school is vastly different from undergraduate school. The students apply with bloated “graduate” grade point averages (typically 3.50 and higher) and contend that they are an entirely different person and we should consider only these new grades. Our experience admitting applicants with these new degrees has not been uniformly good.

SUMMARY:

We are available to discuss admissions with anyone. Just let us know.

Sincerely,
The Authors

References:

1. *Currently, the state of Arkansas contracts with the UTHSC College of Dentistry for 23 slots in each class. The State of Arkansas has arranged for dental slots as well as veterinary medicine, optometry, and other health care specialties. This arrangement is through the Southern Regional Education Board’s “Academic Common Market.” SREB, 592 10th Street; NW; Atlanta, GA 30318*
2. *“Admissions at the University of Tennessee College of Dentistry Part 1: Trend in Applications 1977 – 2015” Journal of the Tennessee Dental Association 96-2, p. 50 – 53 (2017)*
3. *“Zoom” Video Communications, Inc. (2022), San Jose, California*
4. *“Structure of the U. S. Education System: Master’s Degrees” Internal Affairs Office, U. S. Department of Education; July 2008.*
<http://www.ed.gov/international/usnei/edlite-index.html>

The authors:

Dayna D. Myers, RDH, BBA, MDH is an Associate Professor and Director of Admissions Administration at the University of Tennessee Health Science Center College of Dentistry. She is a member of the American Dental Hygienists Association and the American Dental Education Association.

J. Stansill Covington III, DDS, MS is a Professor and Associate Dean for Admissions, Student and Faculty Affairs. He is a member of the American Dental Education Association and a Life Member of The American Dental Association. He holds Fellowship in the American College of Dentists, the International College of Dentists, and the Royal Society of Medicine in London.

FIGURE 1: APPLICANT FLOW THROUGH THE SYSTEM

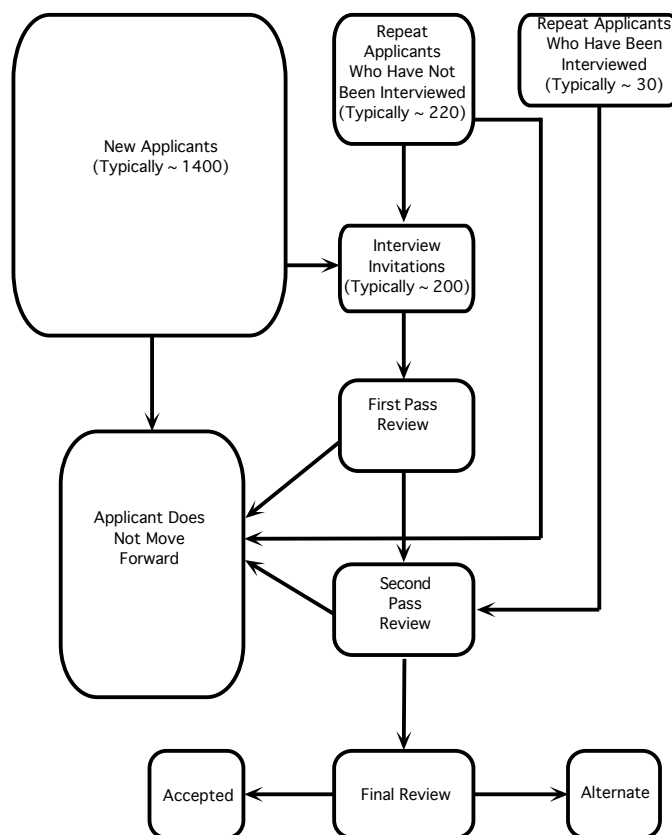


Figure 1 Legend: This diagram shows the basic flow of applicants through the system. The size of the boxes is meant to convey, in general, the number of applicants in that group. Re-applicants automatically proceed to the 2nd Pass Review. Applicants making it past the 2nd Pass Review are either accepted into the class or named as alternates.

TABLE 1

Entering Year	Total Tennessee Applications	Mean GPA	Mean DAT	Interviewed	Offered Position	Accepted Position
2022	134	3.66	20	113	83	72
2021	204	3.67	20	135	86	71
2020	165	3.48	19	115	71	60
2019	158	3.46	19	110	74	64
2018	157	3.53	19	96	70	60
2017	175	3.47	19	77	59	49
2016	192	3.44	19	68	51	46

Table 1 Legend: Applications from Tennessee are shown for the past six years along with mean grades, scores, and admissions data.

Five Generations of dentists in Virginia, Kentucky and Tennessee

Previously published in the Virginia Dental Journal - Reprinted with permission.

Dr. Harold Glenn Speer, Jr.

Dr. G.V. Black is known as one of the founders of modern dentistry and has been called the "Father of Operative Dentistry." In 1857, at the age of 21, Dr. Black began his career in dentistry by serving an apprenticeship under a dentist, Dr. J.C. Speer, in Mt. Sterling, Illinois. While I cannot prove a direct ancestral link to Dr. J.C. Speer in Mt. Sterling, I can establish a link to five generations of Speer dentists in my family originating within a decade of the time that Dr. Black began his studies, including my great-great-great-uncle, Dr. James (Jim) Caswell Speer (1840-1927), who had the very same initials as Dr. Black's mentor (i.e., Dr. J.C. Speer). My great-great-great-uncle, Dr. Jim Speer, a Civil War veteran,¹ settled in Clintwood, Dickenson County, Virginia, passed the Dental Board in 1877² and was recognized as the first licensed dentist to practice in that county.³

My great-great-great-uncle, Dr. Jim Speer, began the first generation of my ancestral Speer dentists, along with his brother, Dr. Spencer Hadley Speer (1842-1911), my great-great-grandfather. After his discharge from the Civil War⁴, Dr. Spencer Hadley Speer returned to his family home on Big "A" Mountain near Honaker, in Russell County, Virginia. He married Mary Catherine Lockhart and learned to practice dentistry under the guidance of his father-in-law, Dr. John Lockhart. The state of Virginia had no dental school or licensing requirements at that time⁵. Dr. Spencer and Mary Catherine had eight children, four sons, and four daughters. Dr. "Spence" Speer practiced dentistry for many years in Honaker and Lebanon, Virginia.

The second generation of Speer dentists included all four of Dr. Spencer Speer's sons who followed the family tradition and became dentists – Dr. Arthur Dallas Speer (1868-1957), Dr. Patrick Speer (1877-1925), Dr. Thomas Speer (1883-1950), and Dr. Samuel Speer (1885-1964).

Dr. Patrick Speer became a successful dentist in Washington,

D.C., where he owned three dental practices, in addition to one he owned in Baltimore. He and his family purchased and resided in the well-known Hickory Hill house in McLean, Virginia – later owned by John and Robert Kennedy⁶.

Dr. Thomas Speer practiced dentistry in Wytheville, Virginia for many years. His younger brother, Dr. Samuel Speer, attended the Medical College of Virginia – Dentistry⁷ and practiced dentistry for many years in Russell and Buchanan Counties, Virginia, and "qualified in the law," according to the biography written by his son, Carl Speer⁸. Dr. Sam Speer's patients included some members of the notorious Hatfield-McCoy feuding families. Dr. Sam Speer's son, Dr. Clyde Victor Speer (1914-1992) practiced dentistry in Wytheville, Virginia for 43 years. Dr. Clyde Speer obtained his dental degree from the University of Toronto, Canada in 1937, but passed the Virginia Dental Board in 1936⁹. Dr. Clyde Speer was a decorated major with the U.S. Army Medical Corps of the 263rd Infantry during World War II.

Dr. Arthur Dallas Speer, my great-grandfather, became an itinerant, or "traveling dentist." He traveled by horse and buggy. He would visit families in Russell, Dickenson, and Buchanan counties. The families would provide him with room and board and a treatment room. He would set up his practice in this home and remain as a guest until he completed the dental treatment for all the family members and some neighbors.



He would perform the necessary oral surgery (extractions), construct dentures or "plates," fabricate gold crowns, and provide the necessary medications or "drugs" to relieve pain and suffering. Families would feed and take care of his horse and buggy during his stay with them. The time required would depend on how many family members lived at this home. The average stay would probably be a week to 10 days. He would accept room and board and care of his horse and buggy as part of his fee for professional service.

These pioneer families looked forward to Dr. Speer's visit because he would bring the latest news of the area. He was a favorite with the children because he would reward them with various gifts for good behavior. He also became a pretty good storyteller in the evenings.

The men folk looked forward to his visit because he always kept a "highbred" horse. Most farms had work or plow horses. A real "high-bred" thoroughbred saddle horse was admired and much desired. The buggy was always the latest model with rubber tires and convertible top, always in polished and clean condition. Many times, Dr. Speer would trade or swap horses with the head of the household.

GOLD CROWNS BECAME FASHIONABLE AND WERE LOOKED ON AS STATUS SYMBOL IN MANY CASES. DR. SPEER WOULD FABRICATE GOLD CROWNS AND CONSTRUCT DENTURES FOR THE LOCALS.

Gold crowns became fashionable and were looked on as status symbol in many cases. Dr. Speer would fabricate gold crowns and construct dentures known as "upper and lower plates" for the locals. He carried a complete supply of dental materials and pharmaceuticals (drugs) in his fancy buggy.


In areas where the mountainous roads were not graded or properly maintained, Dr. Speer would store his buggy with one of the local farmers and travel on horseback. He carried his instruments (tools) and medications in his saddlebags. A "sound" or healthy, easy-riding saddle horse was an absolute necessity. The "doc" always carried two nickel-plated, pearl handled .38-caliber revolvers on his person for protection from "wild critters" and wayfaring strangers." He carried a lot of gold with him, and this placed him at high risk to roadside bandits and robbers. Highwaymen were a constant threat to lonely horseback riders in the mountains of Southwest Virginia and Eastern Kentucky.

Dr. Arthur Dallas Speer traveled to Martin County, Ky., and married Laura Ellen Dempsey, from a large Warfield, Ky. family. He settled down and practiced dentistry in Inez, the county seat of Martin County. He maintained a dental practice in Inez for 50 years. He retired and became a gentleman farmer. Four children were born to this union.

Dr. Arthur Speer's third and youngest son, Dr. Harold Speer, my grandfather, graduated from Inez High School, and since there were only two graduates in the senior class, he was declared the class salutatorian. He then became the third generation of Speer dentists by entering dental school at the University of Louisville, in Louisville, Ky, and later transferring to the second oldest dental school in the United States¹⁰, the Ohio College of Dentistry in Cincinnati, where he earned a Doctor of Dental Surgery degree (D.D.S.) in 1922. Dr. Harold Speer married

Elizabeth Caudill from Letcher County Ky. They had four children: Harold Glenn, Keith Dempsey, Lois and Mildred. Dr. Harold practiced dentistry in several coal mining towns before settling in Grundy, Buchanan County, Va., where he passed the Dental Board in 1936 and practiced for 36 years¹¹.

The fourth generation of Speer dentists began with Dr. Harold Speer's son, Dr. Keith Speer, my uncle, who graduated from Grundy High School in 1944 and served two years in the U. S. Navy in World War II. He earned a B.S. degree from East Tennessee State University, Johnson City, in 1950 and earned a Doctor of Dental Surgery from the Medical College of Virginia, Richmond, in 1955. He practiced dentistry in Grundy, Va., from 1955 to 1996, and was elected and served two terms in the House of Delegates, Virginia General Assembly (1964-68). He retired in 1996 to a small "hobby" farm in Damascus, Va, near the famous Barter Theater in Abingdon, Virginia.





Dr. Keith Speer's brother, Harold Glenn Speer, my father, was the rare exception to the Speer clan, since he strayed from the dental field. He served two years in the U.S. Army Air Corps as a gunner on a B-24, stationed in England during World War II. After the war, he obtained a B.A. degree from Centre College in Danville, Kentucky. He married Ruby Cox from Grundy, Virginia, and returned to the Air Force as a jet fighter pilot who logged over 4000 jet hours and traveled in over 40 countries. After his Air Force career, he settled down in Knoxville, Tennessee with Ruby and raised two sons and three daughters.

The fifth generation of Speer dentists would be ushered in by two of Harold Glenn Speer's children who entered the dental profession. His daughter, Dr. Patricia Speer, went to dental hygiene school at East Tennessee State University, then earned her Doctor of Dental Surgery degree at the University of Tennessee in 1984, and later earned her Periodontal degree from the Medical College of Virginia in Richmond in 1986. Dr. Patricia Speer married another dentist, Dr. Rick Bass, and settled in Norfolk, Virginia, where Dr. Patricia served one term as President of the Virginia Board of Dentistry (1992-1996)¹² and served as a member of the Southeast Regional Testing Agency.

Memphis. Drs. Grace and Buddy Speer began the practice of dentistry in Grundy, Virginia, but later moved to Tennessee where they practiced dentistry for 40 years and served as Captains in the U.S. Army Reserve Dental Corps, 380th Medical Detachment (1989-2000). Along the way, they both earned a Juris Doctor degree at the University of Memphis Law School in 1987 and became licensed Tennessee attorneys, admitted to the bar of the District of Columbia Court of Appeals, as well as the United States Supreme Court. They have one son, two daughters, and three grandsons.

HIS DAUGHTER, DR. PATRICIA SPEER, WENT TO DENTAL HYGIENE SCHOOL AT EAST TENNESSEE STATE UNIVERSITY, THEN EARNED HER DOCTOR OF DENTAL SURGERY DEGREE AT THE UNIVERSITY OF TENNESSEE IN 1984.



Dr Patricia Lee Speer

Harold Glenn Speer's eldest son, Dr. Harold Glenn Speer, Jr., earned his B.A. at the University of Tennessee in Knoxville, and then earned his Doctor of Dental Surgery degree at the University of Tennessee in Memphis, Tennessee in 1981. Dr. Harold Glenn Speer, Jr. or "Buddy" married one of his dental school classmates, Dr. Grace Elizabeth (Hall) Speer, from

¹ U.S. Civil War Soldier Records and Profiles, 1861-1865 – Ancestry.com: James C. Speer served in the 34th Battalion – Virginia Cavalry Company A, Confederate States Army.

² Virginia Dental Association Records, 1998.07.17: 1932 Directory of Dentists registered in Virginia, in the retired list, shows a J.C. Speer, of Cleveland, Virginia who passed the Board in 1877.

³ Sutherland, Elihu Jasper, Meet Virginia's Baby, A Brief Pictorial History of Dickenson County, Virginia, 1955, page 118.

⁴ National Archives and Records Administration (NARA); Washington, D.C.; Compiles Service Records of Confederate Soldiers who Served in Organizations from the State of Virginia; Series Number: M324; Roll: 196. S.H. Speer served in Captain V.A. Witcher's Company of Mounted Rifles, later Company A, 34th Battalion, Virginia Confederate Cavalry (Dunn's Battalion, Partisan Rangers).

⁵ Box / folder, Virginia Dental Association records, Accession # 88/July/17, Special Collections and Archives, Tomkins-McCaw Library, Virginia Commonwealth University, Richmond, Va.:

Since the Civil War over one hundred and fifty years ago, there have been five generations of Speer Dentists serving the people and dental profession of Southwest Virginians, Eastern Kentucky, and Tennessee.

Dr. Spencer H. Speer, 50 years.
Dr. Arthur Dallas Speer, 50 years.
Dr. Harold Speer, 50 years.
Dr. Keith Speer 40 years.
Dr. Harold G. Speer, Jr., 40 years

The following 12 Speer Family members have practiced as dentists:

Dr. James Speer, Dickinson County, VA
Dr. Spencer H. Speer, Russell County, VA
Dr. Patrick (Pat) Speer, Washington, D.C.
Dr. Thomas (Tom) Speer, Tazewell, VA
Dr. Arthur Dallas Speer, Martin County, KY
Dr. Samuel H. Speer, Russell and Buchanan Counties, VA
Dr. Clyde Speer, Wytheville, VA
Dr. Harold Speer, Grundy, VA
Dr. Keith Dempsey Speer, Grundy, VA
Dr. Harold "Buddy" Speer, Grundy VA & TN
Dr. Grace E. (Hall) Speer, Grundy VA & TN
Dr. Patricia Speer, Portsmouth, VA



The procedures for licensing Virginia dentists were still being ironed out in the 1870s. On November 3, 1870, nine Virginia dentists met in Richmond to establish an organization to "cultivate the science and the art of dentistry, and all of its collateral branches, to elevate and sustain the professional character of dentists; and to promote amongst them a mutual improvement, social intercourse, and goodwill." This meeting marked the creation of the Virginia Dental Association (VDA) or Virginia State Dental Association as it was named when first created. The VDA changed to its current name in 1970. The VDA was the successor to the first professional dental organization, the Virginia Society of Surgeon Dentists which was formed in 1842.

An early goal of the VDA was to create standards and regulations for the profession. When the VDA was formed there were no statutes regulating the practice of dentistry in Virginia. The VDA spent several years drafting a bill to present to the state legislature culminating in the passage of the Dental Act of 1886. This act established the Virginia Board of Dental Examiners.

Dental education was another subject of much interest and debate for the VDA. They supported the creation of the first dental school in Virginia in 1893 at the University College of Medicine (UCM). In 1913, UCM merged with the Medical College of Virginia (MCV), which had created its dental school in 1897. For a time, some members of the VDA thought that dentists should obtain an MD degree to practice medicine. The Dental Act only required a diploma and a certificate from the state board to practice dentistry. A dental degree was not required to sit for the state board exam. A law requiring an MD was passed in 1910 but was repealed in 1914 before any provisions were enacted.

⁶ Herrick, Carole L., Chapter 6, "The Speer Residency." Hickory Hill, McLean Virginia: A Biography of a House and Those Who Lived There, pages 53-60.

⁷ The MCV, D yearbook for 1917-1918 shows Dr. Samuel Halley (sic) Speer as a freshman.

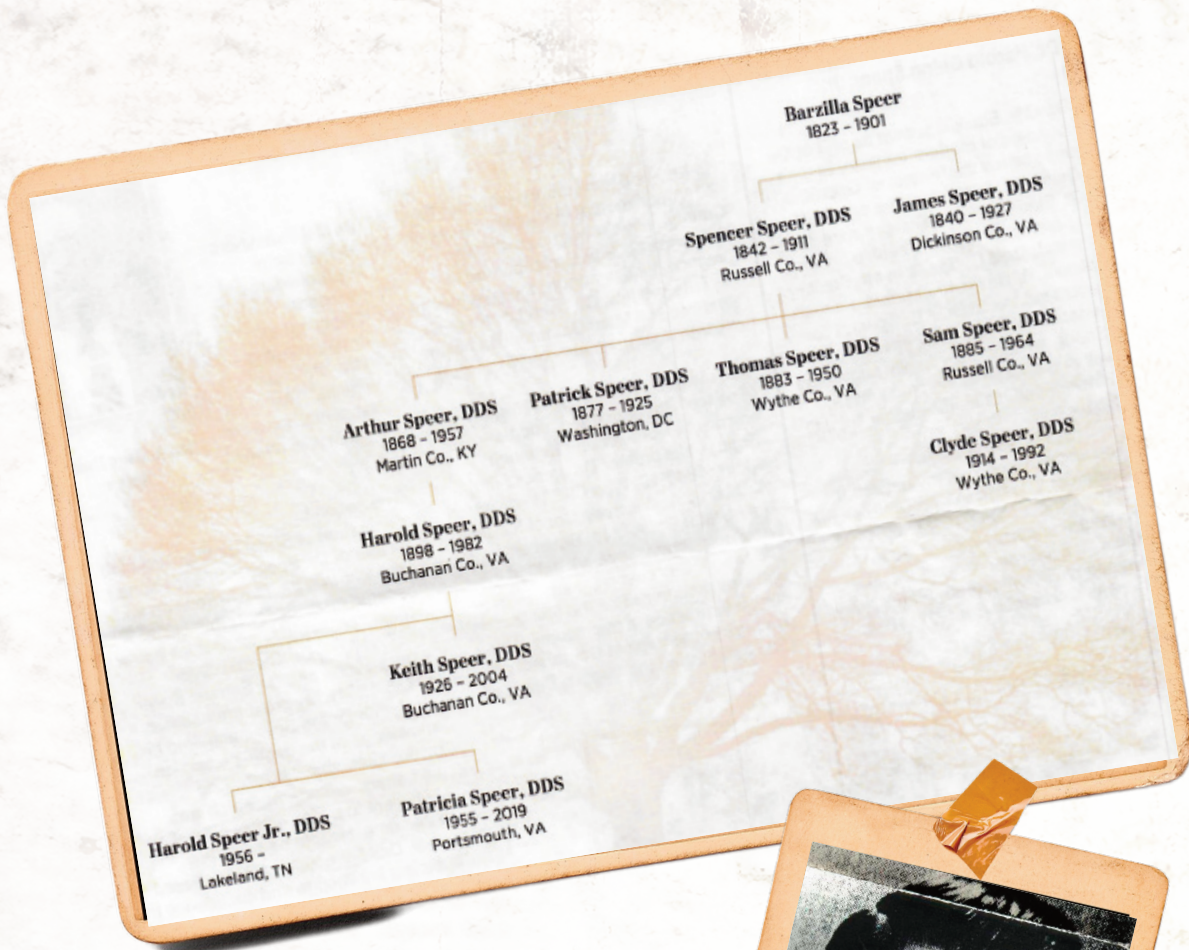⁸ Speer, Carl, From Ritter Hollow, West Virginia to New Zealand, as transcribed by Hélène Everest, a volunteer biographer at Lake Taupo Hospice, March 2015.

⁹ Virginia Dental Association Records, 1998.07.17: 1938 Directory of Dentists registered in Virginia lists a C.V. Speer of Wytheville, who passed the Board in 1936.


¹⁰ Batesel, Paul (emeritus professor of English at Mayville State University in North Dakota), America's Lost Colleges, Profiles of 350 closed or merged colleges - Ohio College of Dental Surgery 1845-1926.

¹¹ Virginia Dental Association Records, 1998.07.17: 1938 Directory of Dentists registered in Virginia lists Harold Speer of Grundy, who passed the Board in 1936.

¹² Virginia Dental Journal, Volume 73, Number 1, January - March 1996, Page 8; Virginia Board of Dentistry Bulletin, Summer 1993, Winter/Spring 1994, Summer 1994, Winter/Spring 1995, Fall/Winter 1995, and Fall/Winter 1996; The Newsletter of the Tidewater Dental Association, Vol. XXXV, No. 1, Winter 1992-1993; The Currents - Portsmouth, Virginia, 25 October 1992, Honors and Awards ("Dr. Patricia L Speer, a periodontist, has been appointed by Gov. L. Douglas Wilder to a four-year term on the Virginia Board of Dentistry.")



Dr Arthur D. Speer



Dr Keith Dempsey Speer



The Dentists
Insurance
Company



**Welcome
to dentistry.**

Looking for exceptional protection from people who understand your profession?
We are **The Dentists Insurance Company, TDIC**, and protecting dentists is all we do.

Our new graduate program makes it easier and more affordable to obtain comprehensive coverage as you're just starting out.

\$50

for your first year of
Professional Liability coverage*

45%

discount in
year two

25%

discount in
year three

No-cost

expert risk management
guidance by phone

Quick & easy

request a quote online

Plan to have coverage through your employer or practice? Talk to our experts about the type and amount of coverage new dentists need.

Learn more at tdicinsurance.com/newgrad.

Scan here:



*First-year TDIC Professional Liability coverage rates are \$0 in AZ and IL, \$50 in ID, TN, MT, OR, WA, AK, CA, HI, MN, NJ, NV, ND and PA. Rates depicted are for new and never-practiced dentists, licensed within the last 12 months and are valid for \$1M/\$3M coverage amounts. Rates increase until a mature policy is reached. The Dentists Insurance Company | 1201 K Street, 17th Floor, Sacramento, CA 95814 | CA Lic. #2361-4

TDA LEADERSHIP POSITIONS FOR 2023-2024

If you are interested in being nominated for one of the following positions, please submit three documents to the TDA by the deadline indicated (required for new nominees only):

1. Letter of Interest
2. CV
3. Conflict of Interest Statement

HOUSE ELECTED POSITIONS

Deadline March 31, 2023

- President-elect (candidates accepted from districts Seven, Eight, and Memphis) *Note: Any qualified TDA member may run for the office of TDA President-elect. Eligibility can be found in Chapter VII, Section 20 of the TDA Bylaws.*
- Speaker of the TDA House of Delegates (Dr. John Petty is eligible for re-election)
- Secretary (Dr. John Petty is eligible for re-election)
- Treasurer (Dr. Jay Davis is eligible for re-election)
- East Tennessee Vice President (candidates accepted from CADS)

TRUSTEE POSITIONS

Deadline January 31, 2023

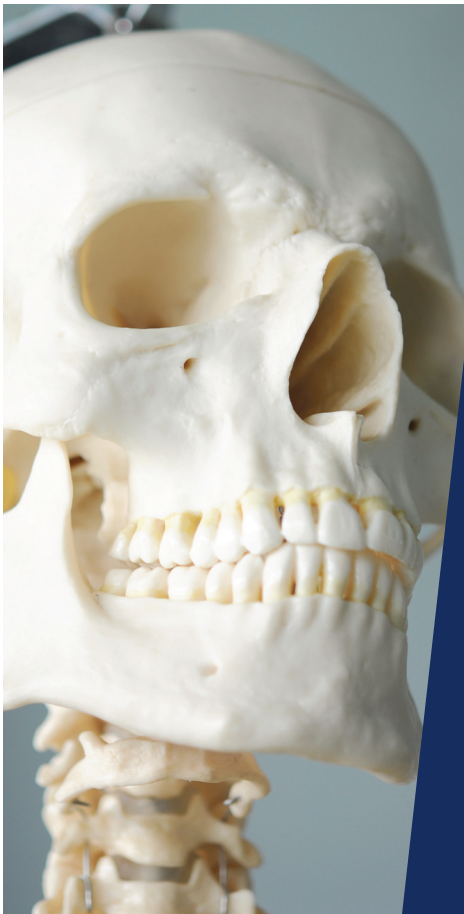Eligibility for trustee positions must be vetted by the TDA Executive Office before election by their component society.

- Trustee / Nashville (Dr. Rhonda Switzer-Nadasdi is eligible for election.)
- Trustee / Eighth District
- Trustee / Memphis (Dr. Stuart Hudsmith is eligible for re-election)

Note: Candidates for Trustee position should complete and return a TDA Conflict of Interest Statement before election by their component.

PLEASE SUBMIT DOCUMENTS TO:

Andrea Hayes, Executive Director
andrea@tndentalassociation.org



Middle Tennessee State University's Forensic Institute for Research and Education (FIRE) presents a two-day seminar on **Forensic Anthropology, Forensic Odontology, Death Investigation, and the Law**

Thursday, October 20 and Friday, October 21
on the MTSU campus in Murfreesboro, Tennessee

Hear from experts in the fields of forensic anthropology, forensic odontology, crime scene and death investigation, law, and forensic medicine.

Experts include world-renowned forensic scientist **Dr. Henry Lee**, who will be the featured speaker.

Get program details and schedule at csimtsu.com.



MIDDLE TENNESSEE
STATE UNIVERSITY.

I AM *true*BLUE.

10 CE hours have been approved by the Tennessee Board of Dentistry.

Online registration begins September 1 and closes October 10. Space is limited.

0822-0967 / Middle Tennessee State University does not discriminate on the basis of race, color, national origin, sex, or disability. See our full policy at www.mtsu.edu/ie.

New MEMBERS

Second District Dental Society

Claire Leiser
Jarrod Lee
Sydney Fain
James Kloer
Bonnie Boudreaux

Chattanooga Area Dental Society

Mitchell Yates

Nashville Dental Society

Alicia Johnson
Anesa Stackhouse
Thomas Veraldi
Janeth Meyer

Seventh District Dental Society

Robert Pruitt

Memphis Dental Society

Ayman Al Dayeh
Mark Whitlock
John Boling
Thomas Darlington
Sahar Moshref
Hayden Huett
Shailja Bhatt



AFTCO
TRANSITION CONSULTANTS
Since 1968

We are pleased to announce...

Carol J. Montee, D.M.D.
has acquired the practice
from the estate of
Barry F. Omohundro, D.D.S.
Nashville, Tennessee

Edward J. Carlone, D.D.S.
has acquired the practice of
Ernest W. Cooper Jr., D.D.S.
Johnson City, Tennessee

Call today for a
FREE MARKET VALUE ANALYSIS
(\$5,000 value)

*We are pleased to have represented
all parties in these transitions.*

800.232.3826 | www.AFTCO.net

Practice Sales & Purchases Over \$3.2 Billion



CONNECTING DENTISTS WITH CUSTOMIZED INSURANCE SOLUTIONS

Since 1994 we've been providing TDA members with customized insurance solutions. We're here whether you need coverage for yourself, your family or your practice. Some of the plans we offer:

- Professional Liability
- Workers' Compensation
- Building and/or Office Contents
- Cyber Liability
- Group Health
- TeleHealth Benefit Program
- Life
- Disability
- Business Overhead Expense
- Auto, Home, Boat, RV, Motorcycle

Contact us for more information!

tda Insurance
AGENCY, INC.

800.347.1109 • TDAInsurance.com

tda
JOURNAL
of the TENNESSEE DENTAL ASSOCIATION

INSTAGRAM

 TNDentalAssn

LINKEDIN


 TNDentalAssn

FACEBOOK

 TennesseeDentalAssociation

TWITTER

 TNDentalAssn



THANK YOU FOR YOUR SUPPORT

THROUGH THE GENEROSITY OF THE INDIVIDUALS AND ORGANIZATIONS BELOW, A TOTAL OF **\$40,294.00** HAS BEEN RAISED FOR THE FOUNDATION DURING ITS FUND DRIVE.

Through the TDAF/Noel Fund for Student Research, the TDAF continues to be a supporter of dental student research. With your support, the TDAF continues to grow and support the future of dentistry.

July 1, 2021 – June 30, 2022
\$1,000 - UP

- George Hopper
- Jerry Hancock
- Gibbs Prevost
- First District Dental Society
- Seventh District Dental Society

\$ 500 - \$ 999

- Dale Dunn
- Mitchel Godat
- Kevin Martin
- Jason Sammons
- Dennis Wells
- Artmas Worthy
- Chad Edwards
- Michael King
- Garrett Orr
- Mitch Baldree
- Karyl Beauchamp
- Marie Farrar

\$ 200 - \$ 499

- Sam Alborz
- Scott Baker
- Robert Clark
- G.Chip Clayton
- Eric Himmelreich
- Daniel Hipps
- Jeff Hunter
- F Steven Kail
- Riley Lunn
- Jon Mather
- Todd Noblin
- William Powell
- Stan Richardson
- James Tyrus
- Stanley Young
- James Allen
- Jeffrey Bell
- Janet Black
- J Allen Burleson
- Fernando Heros
- Elizabeth Jackson

- J. Kennedy
- Rajan Kshatri
- Tammy Kussman
- Elizabeth Lee
- John Martin
- DeWayne McCamish
- Reuben Pelot
- Randall Prince
- David Sain
- Benjamin Scott
- Phillip Shipp
- John H. Sullivan
- Stanley Waddell
- Scott Werner
- James Wilson
- Larry Woods
- Second District
- Jay Davis
- Kenneth Lamb
- Charles McBryer
- James McLaughlin



\$ 100- \$199

Karen Baker-Curtis
 Thomas Faerber
 Kim Glick
 Larry Honeycutt
 William Howard
 Warren Johnson
 Alan Jones
 Victor Kleinaitis
 Keith Logan
 Jerry McKinney
 Jessica Minton
 Richard Myers III
 David Netherton
 Walter Owens
 David Owsley
 Tulsidas Patel

Nilam Patel
 John Petty
 Kathy Sanders
 William Slagle
 Stephen Simpson
 Roy Thompson
 James Vaden
 Wayne Witt
 Jimmy Albright
 Ryan Bowles
 Robert Caldwell
 Mirna Caldwell
 Larry Chambers
 Paul Gilliam
 William Kirkpatrick
 Leon Stanislav
 Bradley White

Tommy Whited
 Lowell Whitefield

UNDER \$ 100

Will Alcorn
 Michelle Adams
 Christopher Anderson
 Philip Arnold
 Robyn Atkinson
 Vincent Atkinson
 Ruth Bailey
 Christopher Bailey
 J Baker
 Damon Barbieri
 David Barnes
 David Barto
 Edsel Bates

Think you might need an associate? Let the pros help you find the right match.

DENTISTS ARE ASKING:



How do I find an associate?
 Where do I find an associate?
 How do I pick the right candidate?



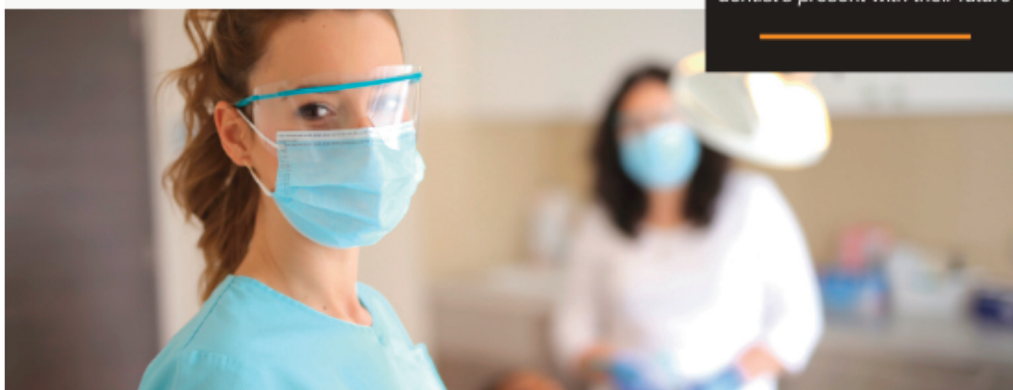Contact Us Today:

Heather Asbury
 heather@ddsmatch.com
1-855-546-0044

Visit Our New Website

-  Create a Profile
-  Connect with Candidates

www.ddsmatch.com



DDSMATCH listened.
 And we have the **SOLUTION**

NEWS & ANNOUNCEMENTS

John M Beasley	Thomas Flanagan	Jeffrey Lancaster	Thomas Rumph
Alan Blanton	Dawn Fleming	Edward Lane	Terry Sawyer
Louis Bonvissuto	Andrew Flipse	William Lee	C Schwepfinger
Jason Botts	Lynn Floyd	Shawn Lehman-Grimes	Scott Self
Gregory Boucek	Stephen Foster	Bertram Lenoir	Candace Settles
Richard Bowles	William Fox	William Lloyd	John Shanks
Nicholas Bowman	Leonard Fuqua	Charles Lowry	James Shoemaker
J Boyd	Robert Galbraith	Mark Luck	Wesley Singer
James Bragg	Tom Gardenhire	Angela Lunn	Travis Sisco
Joseph Britton	Dennis Gardner	David Malin	William Slagle
Joe Brogdon	Derek Gaudry	Jack Mallette	Lucy Sloan
Maria Bryan	Keith Gilmore	Mark Mappes	Michael Solly
Maria Bryan	Brenton Glassell	Stephen Maroda Jr.	Anuj Soni
James Burton	Nathan Glenn	Harvey Matheny	Stephen Speck
Andrew Burton	Matthias Gorham	David Mc Neely	Elizabeth Stanford
James Cade	Anthony Gray	James McCallen	John Stanford
Angela Cameron	Julie Gray	Jackie McClain	David Stanley
Joshua Campbell	Landon Greer	J. Michael McCoy	Randall Staples
Robert Carney	Derrick Gregory	Timothy McNutt	Teresa Stavely
Robert Carney	Vicki Guffey	Ernest Meyer	John Sterrett
Anthony Carroccia	F Rick Guthrie	Richard Moore	Warren Stinson
Philip Carson	David Guy	Tracy Morris	Buffy Storm
James Carter	Katherine Hall	Wallin Myers	John Stritikus
Ellen Carter	Frank Hampson	Mike Mysinger	Carson Taylor
Danny Chacko	Sandra Hayes	Clint Newman	Timothy Thomas
Cordell Chaffin	Kevin Hayes	Steven Nowlin	Mark Thomasson
Patrick Charles	James Hawkins	Susan Orwick-Barnes	Andrew Thomasson
Nathan Chesney	Thomas Heeren	Derek Osborne	Ryan Torti
Gary Chesney	Thomas Heeren	David Otis	Robert Trim
Robert Childress	P Henley	James Owen	Ann Trivette
Sarah Clayton	Vince Hicks	Casey Owen	William Turner
Christian Clinard	James Hight	Tommy Page	John Turner
Marc Cohen	Emanuel Hnarakis	Thomas Patterson	James Vaughn
Jennifer Cole	Jill Hodges	Walter Pattison	Adam Veitschegger
Jennifer Cornell	Charles Hodges	Joseph Payne	Sarah Walker
John Coulter	Paul Holliday	Aaron Payne	Cathryn Wall
Alan Crisman	Dennis Holmes	Russell Peck	James Walmsley
Mark Crumpton	Kenneth Hopkins	Aldrich Perry	Jessica Wang
Adam Davis	Grayson Hunley	Adam Pitts	Paul Warden
Gregory Denton	Douglas Hunter	James Pledger	Dennis Watts
Brian Devine	Glen Hyde	John Primm	Chip Webb
Lucy Digmon	Rachel Hymes	Julia Prince	Elizabeth Webb
Martin Donaldson	Bradley Johnson	Joshua Puckett	J Weir
Amy Duncan	Michael Johnson	Robert Ramsey	Brian West
Kristy Dye	Deborah Jones	Elizabeth Randall	Neil Weston
David Dykes	Derek Jones	Rhett Raum	David Wickness
Kathryn Egan	Rasone Jones	Kevin Reed	Robert Wilhite
Spencer Ellis	Lacy Jones	Charles Roach	John Williams
Taylor Enochs Engler	Robert Kelso	Justin Robbins	J Wills
Tara Ericson	Gregory Kemp	William Roberts	MaryBeth Wilson
Charles Felts	James Kiser	Richard Robinette	Lee Wilson
Nicholas Ferguson	Mary Koen	Gerald Robinson	E Wohnman
Robert Fesmire	David Lambert	Quinton Robinson	Gary Woodall
Robert Fields	Ruth Lambert	Christina Rosenthal	

A New Lab With A Name That's Easy To Remember... And Quality That's Hard To Forget!

***The Dental Lab, Inc. - New to Nashville, but with all
the experience you expect from your lab.***



The Dental Lab, Inc., is a state-of-the-art, full service dental lab featuring high quality crown & bridge, implants and removables. We're a new name in Middle Tennessee... but our owners and technicians have been crafting beautiful smiles here for years. Digital or traditional, The Dental Lab has the expertise to craft any crown, bridge, implant or removable. And we offer FREE pickup and delivery anywhere within a 100 mile radius of the Nashville area. We know it's a leap of faith to try a new lab, but we also know once you do, you'll be saying "Call The Dental Lab" with every new case!

Give us a call with your next case!



Local - 615.942.9964
Toll Free - 888.718.4633
www.thedentalab.net

287 Plus Park Blvd Suite D Nashville, TN 37217



- Right Here In Tennessee!



A Troubling Triad

HOW STRESS, ISOLATION, AND ANXIETY AFFECT SUBSTANCE USE DISORDERS

by DOUGLAS DIXON, DMD, MSD, PHD, MACSD

EDUCATION CREDIT

This article is available to dentists, dental hygienists and dental assistants licensed or registered in Tennessee. With a passing grade, individuals will earn one (1) hour of chemical dependency continuing education credit.

To obtain credit, read the article, answer the questions that follow and return the completed exam page with the appropriate fee to: TDA, 660 Bakers Bridge Ave., Suite 300, Franklin, TN 37067 or fax to 615-628-0214 or take the exam online, pay with a credit card (MasterCard or Visa) and [print your CE](#)

[certificate](#). Visit the TDA's website at www.tndentalassociation.com

If you answer eight (8) questions correctly, you will earn one (1) hour of continuing education credit.

If you have any questions, call the TDA at 615-628-0208.

ADA Principles, Code of Professional Conduct & Advisory Opinions state under 2.D. Personal Impairment that "It is unethical for a dentist to

practice while abusing controlled substances, alcohol or other chemical agents which impair the ability to practice. All dentists have an ethical obligation to urge chemically impaired colleagues to seek treatment. Dentists with first-hand knowledge that a colleague is practicing dentistry when so impaired have an ethical responsibility to report such evidence to the professional assistance committee of a dental society." If you know of a colleague (dentist, dental hygienist or dental assistant) who is impaired, contact the Tennessee Wellness Foundation at 615-628-3200.



“IT IS NON-DISCRIMINATORY AND AFFECTS ALL GENDERS, AGES, SOCIOECONOMIC STATUS GROUPS, AND IS PRESENT IN ALL GEOGRAPHIC REGIONS, STATES, AND COUNTIES ACROSS THE US.”

INTRODUCTION

a. Key Findings from the National Center for Drug Abuse

The “War on Drugs” and chemical dependency is a real and ever-present battle in the US. It is non-discriminatory and affects all genders, ages, socioeconomic status groups, and is present in all geographic regions, states, and counties across the US. According to the National Center for Drug Abuse Statistics “Key Findings” summary (1), there have been over 700K drug overdose deaths since 2000, with almost 20% of the population stating that they have used illicit drugs at least once (would be greater than 60% of the population if alcohol and tobacco were included) and in 2020, the Federal Government budgeted \$35B towards controlling and combating this problem. Of those substances being abused, marijuana, prescription stimulants, and opioids are at the top of the list with drug use ranging from 36-49% among users equating to 7-9% of all adults (1). By 8th grade, 5% of students are using illegal drugs increasing to 24% of high school seniors with almost 50% of students admitting to illegal drug use by the time they graduate from high school (1). Each year, 117K individuals are introduced to heroin use, 1.9M to pain medication, and 3.1M to 4.9M to marijuana and alcohol respectively

b. Deaths from overdose

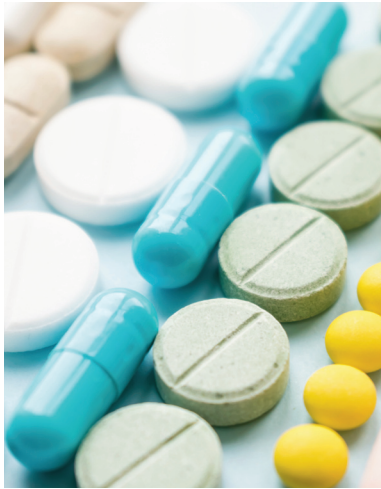Drug overdose was the reported cause of death in over 700,000 fatalities between 1999 and 2017, and accidental drug overdose is the leading cause of death among those under the age of 45 in the US (1). The average life expectancy in the US decreased (between 2015-2017) due to opioid overdose deaths, with fentanyl, prescription opioid, and heroin associated with >28K, >17K, and >15K deaths in 2017 respectively.

¹ Associate Professor and Director, Advanced Education in Periodontics, Associate Professor, College of Dentistry, Department of Periodontology, Memphis, TN

c. Substance abuse and pandemic

After the first reported case of Covid-19 occurred in the US in January 2020, it was reported that by May (2020) that almost 40% of Americans had lost their jobs or had work hours shorted due to the pandemic and associated quarantine that followed.¹ Negative emotions like uncertainty, fear, anxiety, and stress were common coupled with widespread unemployment and social isolation resulted in a substantial negative impact on mental health in many adults in the US.¹ These stressors, and the associated social isolation and unemployment brought on rapidly by the growing pandemic, contributed to a significant spike in substance abuse. During the first three months of the pandemic alone (Jan-Mar 2020), a 15% increase in fatalities due to drug overdoses had occurred as compared to the same quarter in 2019 and by the end of the year, the U. S. Centers for Disease Control and Prevention (CDC) had estimated a record number of drug-related deaths in the US (Avena et al 2021, frontiers in Psychiatry). Social isolation and social distancing may have created additional issues regarding drug use, especially among those with a substance use disorder. Studies suggest that social distancing regulations may have reduced drug trafficking on the streets, thereby forcing those seeking illicit drugs to pursue illegal markets on the internet or through messaging applications.^{2,3} Furthermore, the pandemic may have also caused individuals to abuse readily available medications that were already at home like benzodiazepines^{2,4} or lead to alteration, modification, or dilution of accessible drugs with a potentially harmful substance and/or obtaining synthetic opioids or designer drugs found online.^{2,4}





d. Self-medicating trends and remote workers

The practice of “self-medicating” appears to be a global occurrence with a reported prevalence of 30-80% in both under-developed and developed countries.⁵ It is defined as the utilization of medication, direct drug purchase, or reuse of previously prescribed medications and/or unused medication without medical consultation. Common drugs that are self-prescribed by individuals range from antibiotics and herbal/homeopathic remedies to sedatives and analgesics.^{5,6} During the Covid-19 pandemic, trends for patient self-medication practices increased partly due to widespread medical and medication misinformation on social media prompting practices without established safety and efficacy protocols.^{5,7,8}



According to a recent poll of over 1000 workers, the Sierra Tucson’s Self-Medication National Survey reported a disturbing trend regarding recreational drug and alcohol consumption during the workday. Twenty-five percent of remote workers admitted that they had participated in either zoom or Microsoft Teams while under the influence of recreational drugs, alcohol, or marijuana. Additionally, greater than 25% stated that an added benefit of working from home was the opportunity to use drugs and alcohol during the workday and over 70% of those using alcohol or drugs remotely would miss this opportunity to use drugs if their employer insisted upon a return to the office.

Furthermore, the National Safety Council (NSC) commissioned a survey of employees regarding the impact of opioids on their respective organizations and their awareness of opioid-related issues. Over 525 online interviews were conducted with HR (Decision makers), Mid-level Safety personnel, and Middle to Senior Level Managers was polled. The survey revealed that: Up to 75% of employees in various occupations have been affected by opioid use; 38% of those polled have experience absenteeism or impaired work performance; and 31% reported a near-miss or injury, overdose, or arrest due to opioid use. Another startling finding was that only 17% of these company leaders felt prepared to deal with opioid use in the workplace. This is a shocking revelation when one considers that, for the first time in US history, the NSC has calculated that a person is now more likely to die from an accidental opioid overdose than from a motor vehicle accident.



DEFINING DRUG SCHEDULE AND SUBSTANCE ABUSE TERMS

(TWO TABLES)

a. Drugs are “scheduled” into categories depending on their medical accepted usage and abuse potential. In the US, there are five (5) separate and distinct “schedules” or categories that drugs are grouped into. ^[TABLE 1] has the most common examples of each category. Drugs with the highest abuse potential, which is the main determinate for ranking, are given Schedule 1 classification and these drugs can create a severe psychological, physical, or combined dependency. As abuse potential decreases, the ranking changes with the drugs with the least potential given a Schedule 5 classification. Additional drugs, chemicals, or substances available for clinical practice or research are also given a rank-ordered classification based on abuse potential. ^(Drug Schedule)

b. SUBSTANCE ABUSE TERMS AND VULNERABILITY

Discussion with your patients regarding the use or misuse of medication starts with a background understanding of some common terminology associated with substance use and misuse. According to the Glossary of Terms used in the Surgeon General’s Report on Alcohol, Drugs, and Health (cite book), a substance is defined as a “psychoactive compound with potential to cause health and social problems.” Substance misuse is defined as “the use of any substance in a manner, situation, amount or frequency that can cause harm to users or those around them.” A substance use disorder is defined as, “a medical illness caused by repeated misuse of a substance or substances...characterized by clinically significant impairments in health, social function, etc.” Disorders can range from mild forms which can be sporadic in nature or temporary to severe or chronic forms leading to significant illness, tragedy, and death. Additional terms associated with substance use and misuse can be found on available online web sources like www.samhsa.gov/find-help/disorders and www.nida.nih.gov/nidamed-medical-health-professionals/health-professions-education/words-matter-terms-to-use-avoid-when-talking-about-addiction.

c. Individual vulnerability to substance misuse or substance disorders may be predicted through an assessment of environmental risk factors and personal risk as well as protective factors. ⁹ Environmental risk factors include inexpensive alcohol or other substances, low parental monitoring, family conflict, and heavy advertisement of products to both adults and youths. ^{9, 10} Personal risk factors can include but are not limited to: a family history of substance use/misuse or mental disorders; history of abuse, neglect, or current mental health problem; family conflict or violence; low involvement in school or social groups. ^{9, 10} Although no single environmental or personal risk factor can predict future disorder potential, studies suggest that the highest risk for developing a substance use disorder may be during the adolescent years due to incomplete neurological development in the prefrontal cortex of the brain. Therefore, prevention and intervention attempts targeted at youths may be beneficial as individuals without early risk factors are likely to develop a substance use disorder later in life ^{9, 11, 12}.

SUBSTANCES: WHAT ARE ABUSED AND HOW DOES IT AFFECT THE BODY?

a. OPIOIDS

Opioids and Opiates are used medically and treat various conditions and are prescribed for ailments like cough suppression, moderate to severe pain relief, and diarrhea. The difference between the two is that opiates are created from natural chemical compounds found in plant matter and examples include morphine, opium, codeine, and heroin. In contrast, opioids are formed by creating chemical compounds synthetically. Examples of opioids are fentanyl, methadone, tramadol, and dextropropoxyphene. An exception to this is the partially synthetic opioids which contain some partial components of opium-like hydrocodone, oxycodone, and hydromorphone. The method of action of these drugs affects the brain through the opiate receptors and induces the release of endorphin neurotransmitters which then subdue pain sensations and increase feelings of euphoria and well-being.

Opioids are misused and/or abused when an individual takes prescription medication for non-medical reasons, or in an alternate way other than what was prescribed (e.g., taking someone else’s medication or consuming the drug for its euphoric effects). These drugs are usually ingested but can be snorted, smoked, or injected directly into the bloodstream. According to a report in the National Academies Press in 2017, the age group with the greatest nonmedical use of opioids is young adults (aged 18-25yrs), however, the greatest use and/or exposure of prescription opioids is among adults aged 26 and older.

According to the 2019 National Survey on Drug use and health, almost 10 million people misused prescription pain killers with almost 1 million individuals using heroin in 2019 alone.



b. ALCOHOL

Once ingested, alcohol is absorbed into the blood through the stomach and intestine, crosses the blood-brain barrier, and affects the brain by increasing GABA, a major inhibitory neurotransmitter in the brain.¹³ With increasing amounts, alcohol act like a central nervous system depressant and has a high potential for abuse and tolerance. Chronic alcohol consumption can lead to liver disease creating liver function impairment, which alters the metabolism of certain drugs, disruption of bleeding and clotting functions as well as diminished immune system functionality.¹⁴

According to the National Institute on Alcohol Abuse and Alcoholism (NIH), consumption of alcohol can be defined by the volume/concentration of an alcoholic substance. For example, a “drink” of alcohol is approximately 14 grams of alcohol and can be equated to either a 12-ounce of beer or wine cooler, 5 ounces of wine, or 1.5 ounces of distilled liquor. Moderate alcohol consumption is considered to be no more than 2 drinks per day for males and 1 drink for females. The Centers for Disease Control (CDC) defines “excessive” drinking as: “binge drinking” when women drink 4 or more drinks on one occasion (2-3 hours) and consume 5 or more drinks over the same period; “heavy drinking” 8 drinks/week for females and 15 drinks/week for males; Drinking under the age of 21 or when pregnant is also considered excessive alcohol consumption by the CDC

Assessed 5 JUNE 2022). It is estimated by the CDC that 38 million adults binge drink in the US and over 90% of heavy drinkers also binge drink resulting in almost 90,000 annual deaths in the US each year.

c. OTHER

Many other substances are used, misused, and/or abused by individuals that have a significant impact on not just the individual level, but the family and societal levels as well. Substances like methamphetamines, marijuana, and hallucinogens like LSD or MDMA are also widely used and abused by our patients. Easily obtained substances in over-the-counter-medications (OTCs) like dextromethorphan (used in medications as a cough suppressant) can be taken in large quantities and alcohol can be mixed or used in conjunction with any of these other substances leading to potentially dangerous and dire outcomes. There are many excellent reviews of each of these substances, and their effects, for clinical providers and auxiliary staff members to be made aware of through national and governmental sites as well as the American Dental Academy websites.

SUBSTANCE ABUSE SCREENING TOOLS AND DENTIST INVOLVEMENT

For patient care providers, tools to identify the potential or risk of substance abuse of our patients can be obtained through various online and governmental substance abuse websites. If a suspected use-or-abuse disorder is identified, dentists are then able to make a referral to a local treatment center as appropriate.¹⁵

One such screening tool that has been applied mostly in clinical research settings is the (DAST-10), a structured, self-reported interview with a reported sensitivity (range 41% to 100%) and specificity (range 42% to 99%) both US and international patient populations.¹⁶⁻²⁰

The NIDA Quick Screen questionnaire allows the patient to relate their experiences with alcohol, cigarettes, and other drugs to health care providers.

If the patient says “yes” to the use of illegal or prescription drugs for non-medical reasons, the provider is prompted to proceed into the next, NIDA-Modified ASSIST questionnaire found within the same online document. At the end of the assessment, a patient’s risk level for substance involvement is rated at low, medium, and high risk based on the questionnaire score values.

Another drug abuse assessment tool is the Opioid Risk tool (ORT-ODD) which is also online and accessible through the National Institute on Drug Abuse. This assessment could be administered to patients before, during, or at the initiation of opioid therapy when the patient is being treated for pain management. It uses a simple “yes/no” format related to nine (9) questions divided into three individual topic areas. A patient’s answers are converted into numeric scoring and patients with a total score of 3 indicates a high risk for an opioid use disorder.²¹

THE CONTROLLED SUBSTANCE MONITORING DATABASE PROGRAM (CSMD)

Approximately 20 years ago, a database was established to help monitor the dispensing of Schedule II-IV as well as Schedule V substances by the Controlled Substance Monitoring Act (2002). In 2012 and again in 2016, the prescription Safety Acts improved the monitoring capabilities of the database, and subsequent changes to laws affecting the database were made by TN Together legislation.

The purpose of this prescription drug monitoring program is to collect and maintain controlled substance prescription data dispensed in the State of Tennessee as well as maintaining addition records from other participating States. In Tennessee, it is recommended that before prescribing medications like opioids, benzodiazepines, or any other Schedule II-IV drug that has a potential for abuse, prescribers should query the CSMD systematic the beginning of new treatment or when issuing a new prescription within the first 90 days of treatment. In addition, it is also recommended that one should also check that individual patient’s database at least every 6 months when controlled (prescribed) medication remains part of therapy. Running patient reports require specific patient information to be entered into the database system as well as a date range. Additional frequently asked questions/answers regarding the use of the TN CSMD can be found online at tncsmd.com.

CONCLUSION:

In conclusion, as the prevalence and the untoward effects of substance use and abuse increases, we as health care providers are required to help combat this problem for not only our patients but communities as a whole.

It is essential to understand that our patients are struggling with multiple life stressors and sometimes choosing either unhealthy or potentially dangerous coping mechanisms and habits. In a recent study, over 1800 general practitioners were surveyed regarding their practice of screening patients for drug misuse. (Parrish) Although approximately 75% of respondents reported that they did ask patients about substance misuse, approximately 66% did not feel that such screening was compatible with their professional role. Using the assumption that the average dentist will encounter patients with use/abuse disorders during their practice career, we all must obtain the proper information and training to make informed assessments of our patients and make appropriate referrals to treatment centers for the benefit and welfare of our patients.

References:

1. Avena NM, Simkus J, Lewandowski A, Gold MS, Potenza MN. Substance Use Disorders and Behavioral Addictions During the COVID-19 Pandemic and COVID-19-Related Restrictions. *Front Psychiatry* 2021;12:653674.
2. Zaami S, Marinelli E, Vari MR. New Trends of Substance Abuse During COVID-19 Pandemic: An International Perspective. *Front Psychiatry* 2020;11:700.
3. Schifano F, Chiappini S, Corkery JM, Guirguis A. Abuse of Prescription Drugs in the Context of Novel Psychoactive Substances (NPS): A Systematic Review. *Brain Sci* 2018;8.
4. Rinaldi R, Bersani G, Marinelli E, Zaami S. The rise of new psychoactive substances and psychiatric implications: A wide-ranging, multifaceted challenge that needs far-reaching common legislative strategies. *Hum Psychopharmacol* 2020;35:e2727.
5. Malik M, Tahir MJ, Jabbar R, Ahmed A, Hussain R. Self-medication during Covid-19 pandemic: challenges and opportunities. *Drugs Ther Perspect* 2020;36:565-567.
6. Afridi MI, Rasool G, Tabassum R, Shaheen M, Siddiquiullah, Shujaiddin M. Prevalence and pattern of self-medication in Karachi: A community survey. *Pak J Med Sci* 2015;31:1241-1245.
7. Yang Y. Use of herbal drugs to treat COVID-19 should be with caution. *Lancet* 2020;395:1689-1690.
8. Erku DA, Belachew SA, Abreha S, et al. When fear and misinformation go viral: Pharmacists' role in deterring medication misinformation during the 'infodemic' surrounding COVID-19. *Res Social Adm Pharm* 2021;17:1954-1963.
9. McLellan AT. Substance Misuse and Substance use Disorders: Why do they Matter in Healthcare? *Trans Am Clin Climatol Assoc* 2017;128:112-130.
10. Goldman D, Oroszi G, Ducci F. The genetics of addictions: uncovering the genes. *Nat Rev Genet* 2005;6:521-532.
11. Kessler RC, Berglund P, Demler O, Jin R, Merikangas KR, Walters EE. Lifetime prevalence and age-of-onset distributions of DSM-IV disorders in the National Comorbidity Survey Replication. *Arch Gen Psychiatry* 2005;62:593-602.
12. Hanson KL, Medina KL, Padula CB, Tapert SF, Brown SA. Impact of Adolescent Alcohol and Drug Use on Neuropsychological Functioning in Young Adulthood: 10-Year Outcomes. *J Child Adolesc Subst Abuse* 2011;20:135-154.
13. Most D, Ferguson L, Harris RA. Molecular basis of alcoholism. *Handb Clin Neurol* 2014;125:89-111.
14. Williams N, McElniny, W., . Substance Abuse and Chemical Dependency. In: Wright M, ed. *Academy of Dental Learning and OSHA Training*, 2020.
15. Parish CL, Pereyra MR, Pollack HA, et al. Screening for substance misuse in the dental care setting: findings from a nationally representative survey of dentists. *Addiction* 2015;110:1516-1523.
16. Lam LP, Leung WC, Ip P, et al. Validation of the Drug Abuse Screening Test (DAST-10): A study on illicit drug use among Chinese pregnant women. *Sci Rep* 2015;5:11420.
17. Carey KB, Carey MP, Chandra PS. Psychometric evaluation of the alcohol use disorders identification test and short drug abuse screening test with psychiatric patients in India. *J Clin Psychiatry* 2003;64:767-774.
18. Ghitza UE, Gore-Langton RE, Lindblad R, Shide D, Subramaniam G, Tai B. Common data elements for substance use disorders in electronic health records: the NIDA Clinical Trials Network experience. *Addiction* 2013;108:3-8.
19. Maisto SA, Carey MP, Carey KB, Gordon CM, Gleason JR. Use of the AUDIT and the DAST-10 to identify alcohol and drug use disorders among adults with a severe and persistent mental illness. *Psychol Assess* 2000;12:186-192.
20. Smith PC, Schmidt SM, Allensworth-Davies D, Saitz R. A single-question screening test for drug use in primary care. *Arch Intern Med* 2010;170:1155-1160.
21. Cheatle MD, Compton PA, Dhingra L, Wasser TE, O'Brien CP. Development of the Revised Opioid Risk Tool to Predict Opioid Use Disorder in Patients with Chronic Nonmalignant Pain. *J Pain* 2019;20:842-851.

TABLE 1

DRUG SCHEDULE AND EXAMPLES

DEA DRUG SCHEDULE	ABUSE POTENTIAL	MEDICAL USE	EXAMPLES
(I)	HIGH	NONE	PEYOTE, METHAQUALONE, METHYLENEDIOXYMETHAMPHETAMINE (ECSTASY), LYSERGIC ACID (LSD), HEROIN, 1-(1-PHENYLCYCLOHEXYL)PIPERIDINE, PHENCYCLIDINE
(II)	HIGH	YES	<15MG DOSE OF VICODIN, HYDROMORPHONE (DILAUDID), MEPERIDINE (DEMEROL), OXYCODONE (OXYCONTIN), FENTANYL, COCAINE, DEXTROAMPHETAMINE SULFATE (DEXEDRINE) METHAMPHETAMINE, ADDERALL, RITALIN, PENTOBARBITAL, METHADONE
(III)	MODERATE/LOW	YES	<90MG OF CODEINE (IN COMBINATION WITH TYLENOL), BUPRENORPHINE (SUBOXONE), KETAMINE, ANABOLIC STERIODS, TESTOSTERONE
(IV)	LOWER	YES	ALPRAZOLAM (XANAX), CARISOPRODOL (SOMA), CLONAZEPAM (KLONOPIN), DIAZEPAM (VALIUM), MIDAZOLAM (VERSED), LORAZEPAM (ATIVAN), PENTAZOCINE (TALWIN), ZOLPIDEM (AMBIEN), ULTRAM (TRAMADOL)
(V)	LOWEST	YES	<200MG CODINE OR IN <100MLS OF ROBITUSSIN AC, LOMOTIL, MOTOFEN, LYRICA, PAREPECTOLIN

A troubling triad: how stress, isolation, and anxiety affect substance abuse disorders.

Publication date: Fall 2022. **Expiration date:** Fall 2024

Objectives:

1. To understand the factors contributing to the spike in substance abuse in the US.
2. To understand the effects of substance abuse on individuals.
3. To understand the requisites of the TN Controlled Substance Monitoring Database Program.

1. According to the National Center for Drug Abuse Statistics, how many high school students admit to using illegal drugs by the time they graduate high school?

- a. Almost 10%
- b. Almost 25%
- c. Almost 50%
- d. Almost 75%

2. Each year in the US, approximately 117,000 individuals are introduced into the use of what illegal drug?

- a. Marijuana
- b. Underage alcohol consumption
- c. Heroin

3. Studies from the Centers for Disease Control and Prevention report that during the pandemic, a spike in fatalities of up to 15% was seen in the first 3 months of 2020 as compared to the same 3-month span in 2019.

- a. True
- b. False

4. Which of the following were listed as “factors that may have contributed” to the significant spike in substance abuse in the US during the pandemic?

- a. Stress
- b. Anxiety
- c. Social isolation
- d. Fear
- e. Widespread unemployment
- f. None of the above
- g. All of the above

5. The practice of “self-medicating”, where an individual uses or re-uses medication without proper medical consultation is a problem only seen in the US.

- a. True
- b. False

6. Of those individuals using recreational drugs or alcohol remotely during the workday, what was the percentage of these individuals polled that stated they would miss the opportunity to use drugs if they were forced to go back to the office?

- a. 10%
- b. 20%
- c. 40%
- d. 50%
- e. 70%

7. According to the US National Safety Council, it is more likely to die from an accidental opioid overdose than from a motor vehicle accident.

- a. True
- b. False

8. According to the available research regarding individual susceptibility for substance use disorders, which of the following was suggested to one that may have the highest predictive risk for developing a disorder?

- a. An environmental risk factor like easy access to illegal drugs
- b. A personal risk factor like a family history of drug abuse
- c. Incomplete prefrontal cortex development in the brain during the adolescent years
- d. Low involvement in school activities
- e. Current mental health issues
- f. Heavy advertisement for products to both youths and adults

9. In Tennessee, what is the recommended query timeframe that providers should follow when using the TN Controlled Substance Monitoring Database Program (CSMD) when requesting information regarding patients' prescription history for Schedule II-IV type drugs?

- a. During a new patient procedure that would require pain management drugs
- b. When issuing a new prescription within the first 90 days of treatment
- c. Every 6 months if controlled medication is being prescribed during therapy
- d. None of the above
- e. All of the above

CONTINUING EDUCATION

1. Circle the correct answer on the exam and complete the form below;
2. Mail, along with your check or credit card payment, to: Tennessee Dental Association, 660 Bakers Bridge Ave., Suite 300, Franklin, TN 37067 or fax to (615) 628-0214.

Date: _____ (Credit is granted, upon successful completion of the exam, in the year materials are read and the exam submitted.)

TDA Member Dentist: \$25.00 Hygienist: \$25.00 Registered Assistant: \$25.00 Non-Member Dentist: \$55.00

Name: _____

If dentist, ADA ID Number: _____ District: _____

Address: _____

City/State/Zip: _____

Daytime Phone Number : _____ (_____)

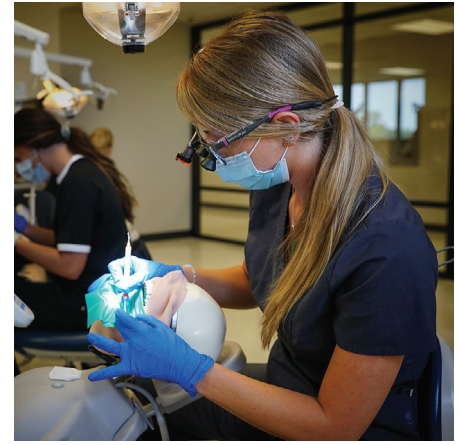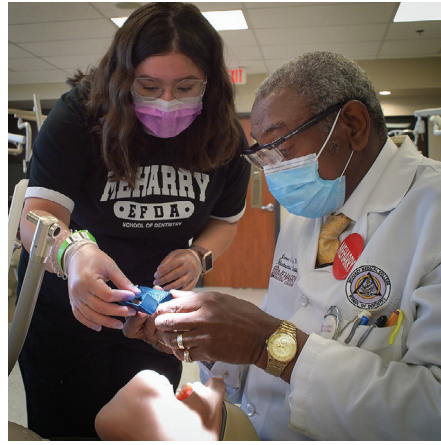Enclosed is my fee of \$ _____ payable to TDA, via check # _____ -or- Process: Mastercard Visa

Name as it appears on the card: _____

Card #: _____ Exp. Date: _____ CVV2: _____
(3 digit code on back of card following the card number)

Signature of Cardholder: _____

You will be notified by mail of your result and credit award. That certificate should be retained in your continuing education file. For TDA member dentists, ACE program credits will automatically be recorded.



DENTAL ASSISTANTS: Expand your skill and knowledge.

Go beyond the earlier scope of your professional training. Meharry Medical College's **Expanded Function Dental Assistant Program in Restorative Function** is a three-week, 96-hour continuing education course approved by the Tennessee Board of Dentistry. Registered Dental Assistants who enroll in the program further their education, can place restorations and prove to be an asset to their dental practice team. Meharry offers Spring, Summer 1, Summer 2 and Fall courses in our state-of-the-art dental simulation lab.

Meharry Medical College School of Dentistry is uniquely positioned to provide EFDA training. Educating dental professionals for nearly 140 years, Meharry's history is steeped in a culture of "health *caring*." Come and train as an EFDA where dental education goes beyond the classroom—at Meharry Medical College School of Dentistry, we teach *health caring*.



S C H O O L O F D E N T I S T R Y

1005 DR. D.B.TODD JR. BOULEVARD • NASHVILLE, TENNESSEE 37208

615.327.6207 • www.mmc.edu

ADA CER.P® | Continuing Education Recognition Program

Meharry Medical College, School of Dentistry, is an ADA CERP Recognized Provider. ADA CERP is a service of the American Dental Association to assist dental professionals in identifying quality providers of continuing dental education. ADA CERP does not approve or endorse individual courses or instructors, nor does it imply acceptance of credit hours by boards of dentistry. Meharry

Medical College designates this live continuing dental education program for 96 continuing education credits. Concerns or complaints about a CE provider may be directed to the provider or to ADA CERP at www.ada.org/cerp.

IMPROVEMENT OF “TIC” SEVERITY

Timothy L. Hottel, DDS, MS, MBA, DBA¹; William L. Balanoff, DDS, MS²; Martha Wells, DDS, MS³

INTRODUCTION

Tourette syndrome (TS) is a neurological disorder characterized by repetitive, stereotypical, involuntary movements and vocalizations called tics. The disorder is named for Dr. Georges Gilles de la Tourette, the pioneering French neurologist who in 1895 first described the condition in an 86-year-old French noblewoman.¹ Once considered rare, TS and Chronic Tic disorders (CTD) have increased in the school-age children population. The onset of TS can be spontaneous or may be preceded by a premonitory urge. By definition, TS is the presence of multiple motor and at least 1 vocal tic present for more than 1 year while CTD includes motor tics or vocal tics (but not both) present for more than 1 year. Tics typically show up between ages 2 and 15, with the average being around 6 years of age. Males are about three to four times more likely than females to develop TS.²

It is estimated that 200,000 Americans have the most severe form of TS, and as many as one in 100 exhibits milder and fewer complex symptoms such as chronic motor or vocal tics. Although TS can be a chronic condition with symptoms lasting a lifetime, most people with the condition experience their worst tic symptoms in their early teens, with improvement occurring in the late teens and continuing into adulthood.¹

Common motor tics involve muscles of the face, neck, and shoulders, while all-

ABSTRACT

This research study was conducted to see if an oral appliance could have a positive effect on the reduction of “tics” commonly associated with Tourette’s Syndrome (TS) and Chronic Tic Disorders (CTD). Patients diagnosed with either TS or CTD were asked to use an oral appliance for ten weeks. 67 patients completed this study. The Yale Total Tic Severity Score (YTTSS) was used to demonstrate any improvement by using a sham or the active oral appliance, the TicTocStop Tic Guard (TTSTG). The TTSTG resulted in an overall 39% reduction in tic severity. One patient reported minor soft tissue discomfort which was resolved and one reported minor drooling. There were no other issues and no serious adverse events reported with either device.

Keywords: Tourettes, Tic, Oral Orthotic, YGTSS, YTTSS

vocal tics involve the oral and pharyngeal structures. With poor or inadequate management of the symptoms of TS, patients are often socially isolated, emotionally distressed, and have difficulty in school, or maintaining employment. Some experience physical pain from intense complex tics. This syndrome currently has no cure, and the etiology is still unclear. Current estimates are that 1 out of 160 children or 0.6% between the ages of 5 and 17 in the US have TS.³

There are several treatment options available including the use of Cognitive Behavioral Intervention for Tics (CBIT)⁴, deep brain stimulation (DBS) which is not FDA approved for use in the United States⁵, and prescription drugs like Clonidine (Catapres), Topiramate (Topamax) and Pimozide (Orap). Unfortunately, the medication route can

have severe adverse side effects, especially for children. Therefore, this route should be avoided when treating children. CBIT can provide patients with a means of control over their tics but can be mentally and physically draining for the patient.

The use of an oral appliance for the treatment of movement disorders was first described by Sutcher et al in 1971.⁶ Anecdotal clinical reports describe the elimination of tics associated with TS by changing the vertical dimension or relationship of a patient’s maxilla and mandible.

Although the exact mechanism of how this works is unknown, the research described in this paper reports the results of a systematic clinical study using an oral orthotic appliance to reduce the number and severity of TS and CTD.

¹ Timothy L. Hottel, DDS, MS, MBA, DBA, FACD

Adjunct Professor, College of Dental Medicine, Lincoln Memorial University, Knoxville, TN

Vice Chair and Chief Examiner, Commission on Dental Testing In Ohio, Columbus, Ohio

² Chief Clinical Officer of Renew, Inc and CEO of Smile Perfected, Inc.

³ Dental director, St. Jude children’s hospital, Memphis, TN. martha.wells@stjude.org

METHODS & MATERIALS

Before acceptance into this clinical trial, patients with medically diagnosed TS or CTD were screened by a licensed Cognitive Behavioral Intervention for Tics Certified Therapist nurse who was trained in CBIT. Using a recognized survey instrument, the Yale Total Tic Severity Score (YTTSS), patients' progress, if any, was documented before admitting a patient to the study, after wearing the sham appliance for one week, after wearing the orthotic for one week and then throughout the remainder of the study to assure compliance and document any tic reduction or adverse side effects.

Oral Orthotic Appliance

The appliance was constructed using a polyethylene base with an ethyl vinyl acetate liner to make it retentive on the teeth. This combination of materials is known commercially at Kombiplast (Dentsply Sirona, USA). A prefabricated arched trapezium acrylic block (ATB) of poly methyl-methacrylic (PMM) known as Biocryl X (Great Lakes Orthodontics, NY) is chemically welded to the base, adjusted to the patient's bite, polished, and returned. The ATB is designed to provide occlusal contact from the second molar to the first premolar. The ATB also allows more room for the tongue on the lingual, helps prevent biting the tongue and can allow for better linguistics while the patient wears the orthotic. The buccal portion of the ATB is designed to provide support to the buccinator's muscle to prevent or avoid cheek biting.

Visit 1

After review and acceptance of the study's Informed Consent by the patient or their legal guardian, a complete medical and dental history was taken including a comprehensive oral exam. In addition, a cone beam radiograph (CBCT) was obtained and reviewed by a boarded dental radiologist to see if there were any common abnormalities present that might help in the understanding of the disease or how the appliance works.

To find the ideal change in vertical dimension for the active appliance, the patient was asked to bite on increasing numbers of 1mm thick wood tongue

blades that were placed in their first molar area with the mandible moved slightly forward. The stick(s) remained in place for three minutes while the number of tics was recorded and documented by videotaping. Additional 1mm increases in the opening were done in the same manner until the maximum reduction in tics was observed and the additional opening had no further reduction in tics or in some cases, the increased tics. At this point, a bite registration was obtained using Regisil Rigid VPS (Dentsply Sirona, USA) with the stick(s) in place so that the lab could replicate the opening and position of the arches. Full arch upper and lower impressions were taken using Aquasil Easy Mix Putty (Dentsply Sirona, USA) as the impression material. The resultant impressions and bite were then sent to a dental laboratory (Impact Dental Lab/Oral Care Perfected, Dania Beach, FL) to produce the prescribed sham and active appliances (see Figures 1 & 2).

Visit 2

On the second visit and at all remaining visits, the patient was asked if there was any change in their medical history, especially any change in their medications. An oral examination was performed to assess if there were any dental issues or if the device was causing any problems. Also, any questions from the patient were addressed. Before each appointment, a YTTSS assessment was completed by the CBIT-trained nurse.

A three-minute video was taken without anything in the patient's mouth then the inactive sham appliance was placed, adjusted if necessary, and an additional 3-minute video was obtained with it in place. All tic counts were recorded in the patient's chart. This inactive sham appliance was used to see if the patient could tolerate wearing an appliance and to see what effect it might have on their tics when compared to the active appliance.

Visit 3

On this visit, the patient was video recorded without any appliance, then with the sham appliance, both for three minutes. Next, the active TTSTG appliance was inserted, and adjusted to

make sure that it didn't impinge on the soft tissue and that the bite was level. An additional 3-minute video was recorded after the TTSTG was placed and adjusted. Again, the tic count was documented in the chart.

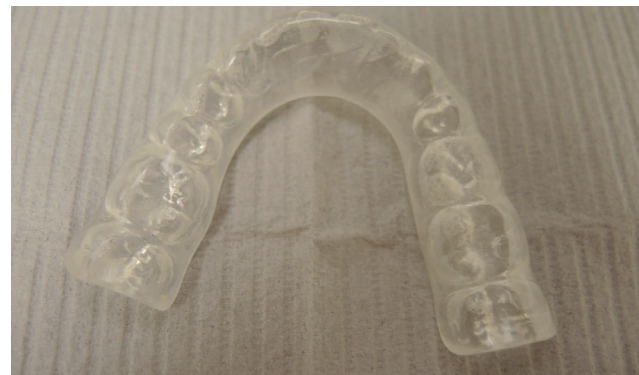

Figure 1 Inactive (sham) appliance made of a soft flexible base (Kombiplast)

Visit 4

The patient returned after wearing the active TTSTG for one week and the three-minute video was taken without the appliance, then again with the active appliance. The number of tics was documented in the chart. Since the patient would not be seen for two months, the patient was instructed to contact any clinician in the study if they had any problems with the TTSTG.

Visit 5

On this 5th and final visit, a more detailed history was taken due to the length of this time the patient used the TTSTG. After three-minute videotaping with and without the orthotic, an exit interview was completed. The patient was allowed to keep the TTSTG with instruction to contact any one of the clinicians in the study if there were any future issues with the active orthotic appliance.

Study Design and Procedures

The study was approved by the University of Tennessee Institutional Review Board (IRB), approval number 14-0382-FB, and was also registered at ClinicalTrials.gov, ID NCT02599519. The study was conducted at two investigation sites; Memphis, Tennessee, and Long Island, New York.

Once the TTSTG was functional, the study was designed with a 12-week interval to avoid the disruption of skeletal growth, as well as anticipate tooth loss, which could require adjustments to be made to the TTSTG. The personnel recording the YTTSS observations remained unchanged at both clinical sites throughout the study.

At each visit where the YTTSS was taken, the assessor recorded how often they wore the sham or TTSTG device. Because the patient wears the device only when they want to control the urge to tic and not 24 hours a day, patients were not required to keep a log.

Outcome

The primary endpoint of this pivotal study was the assessment of changes in the YTTSS. The YTTSS is a clinical rating instrument designed for use in studies of Tourette’s syndrome and other tic disorders.⁷ The reliability and validity of the Yale Global Tic Severity Scale (YGTSS), including the YTTSS portion of the scale, has been previously established in adults and children⁸. The study design threshold was a 27% decrease in overall tics. The 27% reduction in tics was chosen as it was considered clinically meaningful to the patient.

Statistical Analysis

Analyses were conducted using SAS for Windows version 9.3 or later (SAS, Cary, NC). Data were summarized using descriptive statistics. For continuous measures, this includes a number (n), mean, standard deviation (SD), median, and range (minimum and maximum). For categorical measures, counts and percentages were provided. All statistical tests were conducted at $\alpha = 0.05$ with a two-sided significance level.

The null hypothesis is that a placebo orthotic and the TTSTG orthotic are not different in mitigating the severity and frequency of tics associated with medically diagnosed TS and CTD when measured using the YTTSS. The parameters of the design dictating the recommended sample size of sixty-five (65) patients are based upon the following measurements: Significance level: 0.05, Standard Deviation: 0.5,

Power Number: 0.80, Minimal Detectable Difference: 0.27, Drop-out Rate: 14%.

Results/Discussion

After interviewing multiple candidates that applied to be part of the study, a total of 77 subjects met the enrollment qualifications and were admitted into the study with 58 (86.6%) completing the study. The demographics of the study participants don’t reflect the individuals present in the general population of Tourette’s patients but instead represent the individuals that applied and met the guidelines for this study. Nine (13.4%) subjects discontinued the study. The mean (SD) age of subjects was 15.5 (8.56) years. The majority of subjects were male (74.6%) and white (94.0%). The average (SD) age when motor tics and vocal tics first occurred was 6.9 (3.12) years and 8.0 (3.48) years, respectively. The average (SD) age when the worst motor tics and vocal tics first occurred was 11.4 (6.57) years and 11.2 (5.49) years, respectively. A total of 36 (53.7%) subjects used concomitant medications.

The development of a non-invasive, minimal side effect device, proven to effectively eliminate or minimize tics, would greatly benefit patients with TS and CTD. This research details the results from a clinical study evaluating the effectiveness of the oral orthotic device, the TTSTG, developed by TicTocStop, Inc, against a sham/placebo device. We monitored the patient’s dental/oral health, measured their baseline symptoms, and compared these findings after utilization of the sham and active orthotic device. The objective of this study was to 1) evaluate the safety of a custom-fitted oral orthotic device in patients with TS or CTD; 2) evaluate and demonstrate the efficacy of an oral orthotic device to decrease motor and vocal tic severity in a patient with TS or CTD.

The study assessed the effectiveness of the TTSTG in mitigating motor and vocal tics in children and adults with TS and CTD. Our results are shown here to describe a statistically significant improvement in the YTTSS with both the sham appliance and the TTSTG with a more robust improvement with the

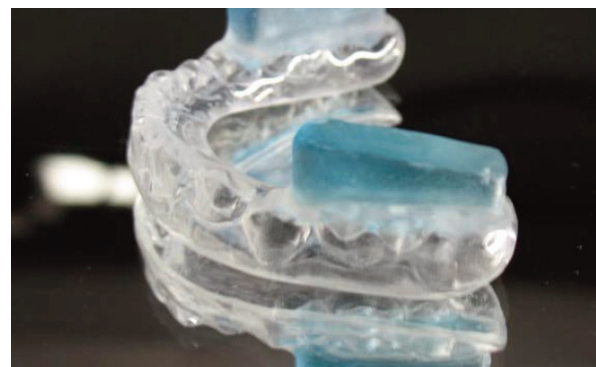


Figure 2 Active appliance made of a soft flexible base (Kombiplast) and the rigid bite area (Biocryl X)

TTSTG when compared to the baseline (no appliance). The sham appliance resulted in a 25% overall reduction in tic severity while the TTSTG resulted in an overall 39% reduction in tic severity and frequency (Tables 1) with similar reductions in individual motor tics of 33% (Table 2) and vocal tic reduction of 41% (Table 3). No serious adverse events were reported with either device and only two minor reports: one of soft tissue discomfort which was resolved and one of minor drooling. This study demonstrates a significant reduction in YTTSS using the TTSTG with no reported serious adverse events therefore this device should be added to the treatment modalities offered to patients with TS/CTD.

Conclusion

The study does not answer "why" the TTSTG works to reduce motor and vocal tics in children and adults with TS and CTD, and this remains an area of active investigation. Our study demonstrated quite clearly that opening the vertical dimension mitigated the tics in all test subjects. Understanding where the condyle is in relationship to the articulate eminence and fossa will guide us in the direction of "why" this is working. The long-term implications outpace this study design. Perhaps a treatment modality would be craniofacial surgery to correct a maxilla/mandibular discrepancy. Perhaps interceptive orthodontics on patients with a family history of TS or CTD and a propensity toward a Class II occlusion would be a patient population that would require early screening and treatment.

TABLE 1: CHANGE FROM BASELINE TO WEEK 11 IN YTTSS TOTAL TIC SEVERITY SCORE

Parameter Timepoint

	TTSS Baseline ^a	Week 11	Change from Baseline	% Change from Baseline ^c
n	58	58	58	58
Mean (SD)	27.4 (10.36)	17.5 (10.07)	-9.9 (8.13)	-35.9 (38.70)
Median	29	17.0	-10.0	-38.8
Min, Max	6, 45	0, 50	-25, 18	-100, 156
95% CI _b			(-12.0, -7.8)	(-46.1, -25.7)
p-value _b			<0.001	<0.001

a: Baseline is defined as the end of the one-week placebo run-in period

b: From a one-sample t-test

c: If a subject has a score of 0 at baseline, the percent change is missing

TABLE 2: CHANGE FROM BASELINE TO WEEK 11 IN YTTSS TOTAL MOTOR SEVERITY SCORE

Parameter Timepoint

	TTSS Baseline ^a	Week 11	Change from Baseline	% Change from Baseline ^c
n	58	58	58	55
Mean (SD)	15.9 (5.64)	10.8 (5.47)	-5.1 (5.07)	-34.3 (31.47)
Median	16.0	11.0	-5.5	-33.3
Min, Max	0, 25	0, 25	-16, 10	-100, 67
95% CI _b			(-6.4, -3.8)	(-42.8, -25.8)
p-value _b			<0.001	<0.001

a: Baseline is defined as the end of the one-week placebo run-in period

b: From a one-sample t-test

c: If a subject has a score of 0 at baseline, the percent change is missing

TABLE 3: CHANGE FROM BASELINE TO WEEK 11 IN YTTSS TOTAL VOCAL SEVERITY SCORE

Parameter Timepoint

	TTSS Baseline ^a	Week 11	Change from Baseline	% Change from Baseline ^c
n	58	58	58	48
Mean (SD)	11.5 (6.79)	6.7 (6.48)	-4.8 (5.43)	-49.1 (39.00)
Median	12.0	8.0	-5.0	-40.9
Min, Max	0, 23	0, 25	-17, 14	-100, 47
95% CI _b			(-6.2, -3.4)	(-60.4, -37.8)
p-value _b			<0.001	<0.001

a: Baseline is defined as the end of the one-week placebo run-in period

b: From a one-sample t-test

c: If a subject has a score of 0 at baseline, the percent change is missing

References:

1. Mayo Clinic Patient Care & Health Information, Tourette's Syndrome, Retrieved from <https://www.mayoclinic.org/diseases-conditions/tourette-syndrome/symptoms-causes/syc-20350465>, 12/13/18.

2. National Institute of Neurological Disorders and Stroke, Tourette Syndrome Fact Sheet, Retrieved from <https://www.ninds.nih.gov/Disorders/Patient-Caregiver-Education/Fact-Sheets/Tourette-Syndrome-Fact-Sheet>, 12/13/18.

3. Hottel, T.L., Jack, R.L., Taynor, E., Wells, M., Brandt, R.,

Hottel, S.A. & Balanoff, W.: Improved Yale Total Tic Severity Score due to craniofacial manipulation with an oral appliance, *Compendium*, 40 (1), 2019.

4. Piacentini, J., Woods, D. W., Scahill, L., Wilhelm, S., Robertson, A. L., Chang, S., et al. Behavior therapy for children with Tourette disorder: a randomized controlled trial, *JAMA*. 2010, 303, 1929-1937.

5. Servello, D., Porta, M., Sassi, M., Brambilla, A., Robertson, M. M. Deep brain stimulation in 18 patients with severe Gilles de la Tourette syndrome refractory to treatment: the surgery and stimulation, *J Neurol Neurosurg Psychiatry*. 2008, 79, 136-142.

6. Sutcher, H. D., Underwood, R. B., Beatty, R. A., Sugar, O. Orofacial dyskinesia. A dental dimension, *JAMA*. 1971, 216, 1459-1463.

7. Leckman, J.F., Riddle, M.A., Hardin, M.T., Swartz, K.L., Stevenson, J., et al. The Yale Global Tic Severity Scale: initial testing of a clinician-rated scale of tic severity, *J Am Acad Child Adolesc Psychiatry*, 1989, 28, 566-573.

8. Storch, E. A., Murphy, T. K., Geffken, G. R., Sajid, M., Allen, P., Roberti, J. W., et al. Reliability and validity of the Yale Global Tic Severity Scale, *Psychol Assess*. 2005, 17, 486-491.

Improvement of “tic” severity with the use of an oral appliance in patients diagnosed with Tourette’s Syndrome

Publication date: Fall 2022. Expiration date: Fall 2024.

Objectives:

After reading this article, a dentist should be able to:

1. Understand the importance in the role a dentist may be able to play in a patient with Tourette’s Syndrome and/or motor and vocal tic disorders.
2. Describe how a simple oral appliance may reduce the “tics” in a patient diagnosed with Tourette’s Syndrome and/or motor and vocal tic disorders.
3. Understand the role that vertical dimension plays in mitigating the “tics” in a patient with Tourette’s Syndrome and/or motor and vocal tic disorders.

1. Tourette’s Syndrome is becoming more common in the US and is defined as:

- a. Including only a motor tic
- b. Including only a vocal tic
- c. Is always preceded by a premonitory urge
- d. Including multiple motor and at least 1 vocal tic

2. There are several treatment options which include:

- a. CBIT
- b. DBS
- c. Prescription drugs
- d. Only b and c
- e. All of the above

3. The patients in this study had:

- a. No change in their tics
- b. Almost a 40% reduction in their tic severity
- c. Only a change in their vocal tics
- d. Only a change in their motor tics

4. This study only included children since adults don’t have TS or CTS since they always grow out of these neurological issues:

- a. True
- b. False

5. The sham and active orthotic appliance have a base made from ethyl vinyl acetate in order to:

- a. Give the appliance structural rigidity
- b. Insure that the bite material and base bond to each other
- c. Form a liner to make the appliance retentive on the teeth
- d. All of the above
- e. None of the above

1. Circle the correct answer on the exam and complete the form below;
2. Mail, along with your check or credit card payment, to: Tennessee Dental Association, 660 Bakers Bridge Ave., Suite 300, Franklin, TN 37067 or fax to (615) 628-0214.

Date: _____ (Credit is granted, upon successful completion of the exam, in the year materials are read and the exam submitted.)

- TDA Member Dentist: \$25.00 Hygienist: \$25.00 Registered Assistant: \$25.00 Non-Member Dentist: \$55.00

Name: _____

If dentist, ADA ID Number: _____ District: _____

Address: _____

City/State/Zip: _____

Daytime Phone Number : _____ (_____)

Enclosed is my fee of \$ _____ payable to TDA, via check # _____ -or- Process: Mastercard Visa

Name as it appears on the card: _____

Card #: _____ Exp. Date: _____ CVV2: _____
(3 digit code on back of card following the card number)

Signature of Cardholder: _____

You will be notified by mail of your result and credit award. That certificate should be retained in your continuing education file. For TDA member dentists, ACE program credits will automatically be recorded.

TRANSLUCENCY STABILITY OF TWO FLEXIBLE DENTURE BASE MATERIALS

after staining and exposure to cleansing agents

David E. Umsted, DDS, James C. Ragain, Jr., DDS, MS, PhD, Alexander Dozier, DDS, Brian R. Morrow, MS, Franklin Garcia-Godoy, DDS, MS, Ph.D., PhD

David E. Umsted, DDS
Associate Professor
Department of Prosthodontics, College of Dentistry
The University of Tennessee Health Sciences Center

James C. Ragain, Jr. DDS, MS, PhD
Professor and Dean, College of Dentistry
The University of Tennessee Health Sciences Center

Alexander C. Dozier, DDS
Former dental student. Currently in private practice in Nashville, Tennessee
The University of Tennessee Health Sciences Center

Brian R. Morrow, MS
Senior Research Specialist, Department of Bioscience Research, College of Dentistry
The University of Tennessee Health Sciences Center

Franklin Garcia-Godoy, DDS, MS, Ph.D., PhD
Professor, Department of Bioscience Research, College of Dentistry
The University of Tennessee Health Sciences Center

Corresponding author:
David E. Umsted, DDS
Associate Professor,
Department of Prosthodontics, College of Dentistry
The University of Tennessee Health Sciences Center,
875, Union Ave, Memphis, TN-38163
dumsted@uthsc.edu

Keywords: *Flexible / Removable Partial Denture, Denture Cleanser, Prosthodontics, Translucency, Staining,*

ABSTRACT

Purpose: Currently, there is limited research reported on flexible removable partial dentures (FRPDs). One of the main advantages of FRPDs is their translucency as it blends well with the existing soft tissues. To compare the change in the translucency of two of the most used flexible denture base materials after immersion in different beverages and cleansing with two denture cleaners.

Methods: Forty specimens each of denture base materials were made. Baseline L*a*b* color parameter measurements were made on each specimen first on black backing and then on white backing using a reflectance spectrophotometer. Translucency Parameters (TPs) were calculated for each specimen using D65 illumination with the specular component excluded. Specimens were then placed in their respective storage solutions, which were coffee, cola, red wine, and deionized water. Specimens were re-measured after 20 days, and TPs were calculated. After staining was completed, half of the specimens in each group were cleansed with two different denture cleansers for 7 days and re-measured. Data were analyzed by ANOVA (P= 0.05) with postdoc Tukey HSD.

Results: At baseline, one material demonstrated greater translucency than the other. There were significant changes in TP for one material after staining for 20 days but not for the other.

Conclusion: One material had a greater loss in translucency after staining than the other. One material cleansed with a cleaner had a greater recovery of translucency than the same material cleansed with another cleanser, or the other denture material cleansed with cleaner.

Keywords: *Flexible / Removable Partial Denture, Denture Cleanser, Prosthodontics, Translucency, Staining,*

Keywords: Tourettes, Tic, Oral Orthotic, YGTSS, YTTSS

INTRODUCTION

Polymethylmethacrylate (PMMA) polymers are used as denture base materials since 1937 and are still the primary material of choice for complete dentures and removable partial denture base materials. The clinical use of flexible materials as an alternative material in the fabrication of removable partial dentures (RPDs) is rapidly growing. Although a survey taken in January 2011 demonstrated that 70% of all dentists are prescribing flexible RPDs and 26% of all RPDs are flexible,¹ there is limited research reported on these materials. One of the main advantages of flexible RPDs is their translucency. It is advertised that the translucency of the materials blends well with the existing soft tissues, making the partial indistinguishable in the mouth.² Clinically the physical properties of flexible RPDs degrade over time. Alterations in color and gloss and the presence of staining have been reported.³ This could result in patient dissatisfaction and the need for the replacement of the prosthesis. This study compared the change in the translucency of two popular flexible denture base materials after immersion in different beverages and cleansing in different over-the-counter cleansers.

Materials and Methods: Forty specimens each of flexible partial denture material DuraFlex (The Myerson Company Ltd., Laventille, Trinidad and Tobago) and TCS (Thermoplastic Comfort Systems, Inc. Signal Hill, CA, USA) were fabricated.

The staining treatment agents used were coffee (Starbucks Pike Place Starbucks, Seattle, WA, USA), cola (Coca-Cola, The Coca-Cola Company, Atlanta, GA, USA) red wine (Cabernet Sauvignon, Sutter Home Winery, Inc. St. Helena, CA, USA), and deionized water (DI).

The cleansing agents used were Polident (GSK, Philadelphia, PA, USA) antibacterial denture cleanser and TCS Fresh (Thermoplastic Comfort Systems, Inc. Signal Hill, CA, USA) concentrated dental appliance cleaner.

Each specimen was measured with a spectrophotometer (Spectrophotometer CM-700d, Konica Minolta Sensing Americas, Ramsey, NJ, USA) to provide baseline data. Ten specimens of each material were placed in one of four

beverages. The beverage groups were coffee, cola, red wine, and deionized (DI) water as a control. After 20 days of immersion, the specimens were remeasured. After staining, half of the specimens were cleansed using Polident and the other half using TCS Fresh cleaner. Specimens were measured again after cleansing. Measurements included both Specular Component Included (SCI) and Specular Component Excluded (SCE). Changes in translucency after staining and cleansing were recorded, and data analyzed using appropriate statistical tools.

Specimen preparation: Forty specimens were made for each material. The DuraFlex and TCS specimens were fabricated in a commercial dental laboratory according to the manufacturer's instructions. Wax patterns with sprue formations were invested in specially designed flasks. The wax patterns were eliminated through a boil-out and wash-out procedure. DuraFlex and TCS used the closed-flask method of injection. After heating and melting in a specially designed furnace the material was injected under pressure into the flask using a specially designed press. After cooling, the material was finished by hand using a succession of abrasives and rubber wheels. Polishing was accomplished with pumice and a high shine compound. The same finishing and polishing techniques that are normally used for DuraFlex and TCS partial dentures were used to manufacture the specimens. Circular specimens were 2.0 mm in thickness and 10 mm in diameter. The specimens were labeled and stored in deionized water at 22°C until baseline color measurements were obtained and specimens were assigned to experimental treatment groups.

Measurement procedure: One side of each specimen was marked with a small notch placed with a carbide bur so that all measurements would be taken from the same side of the specimen. A custom specimen holder was made to stabilize the specimen during measuring to ensure that all measurements were taken from the same point on the specimen. In addition, the inner surface of the stainless-steel specimen holder was highly polished to reflect light into the

specimens and prevent edge loss. Edge-loss occurs during reflectance measurements of materials when light is scattered within a specimen beyond that part of the surface exposed to the observation system of the optical device. When this happens, the lost light is not detected by the sensor of the spectrophotometer and results in an inaccurate measure of color.⁴ The custom specimen holder redirects light that would not be measured during conventional measurement back into the specimen.⁵

Before staining (Day 0) baseline measurements were obtained using a spectrophotometer. This is a hand-held device containing a lamp, which provides a beam of light. The light beam strikes a diffraction grating, which acts as a prism and separates the light into its component wavelengths. The grating was rotated so that only a specific wavelength hits an exit slit. The exiting beam then interacts with the specimen and a detector measures the transmittance and absorbance of the specimen. Transmittance is the amount of light that passes completely through the specimen and strikes the detector. Absorbance is a measurement of light that is absorbed by the specimen. The detector sees the transmitted light and converts this information into a digital display.⁶ Six measurements were taken for each specimen and a mean was obtained from the six measurements.

Staining and cleansing: Individual specimens were fully immersed in respective staining solutions at 22°C. They were stored in staining solution for 20 days and solutions were changed every other day due to potential fungal growth in the solutions. Remeasuring occurred after an addition 20 days. Before each remeasurement the spectrophotometer was recalibrated using the black and white calibration standard and each specimen was lightly rinsed in DI water for 10 seconds and carefully blotted dry with soft absorbent paper tissues. All measurements were taken and recorded by the same investigator to minimize inconsistency of measurement techniques. Following staining, half of each staining solution group specimens were cleansed in their respective denture cleanser daily for 7 days. The manufacturers' instructions were followed for each cleanser. Those cleaned in Polident were soaked for 5 minutes each and then rinsed and returned to a DI water storage solution. Those cleansed with TCS cleanser were soaked daily for 30 minutes and then returned to a DI water storage solution. Specimens were remeasured again after cleansing for 7 days.

Measurements and calculations:

During color measurement, each specimen was placed in the spectrophotometer and the reflectance spectra were determined in the visible light range ($\lambda = 390 \text{ nm to } 780 \text{ nm}$).

Color parameters were determined using the CIE $L^*a^*b^*$ color space model. The color differences were determined using the ΔE^*_{ab} (CIE 1976):

$$\Delta E^*_{ab} = \sqrt{(L_2^* - L_1^*)^2 + (a_2^* - a_1^*)^2 + (b_2^* - b_1^*)^2}$$

where.

$L^*_2 - L^*_1$ is the difference in the white to black CIE $L^*a^*b^*$ color parameter. $a^*_2 - a^*_1$ is the difference in the red to green CIE $L^*a^*b^*$ color parameter. $b^*_2 - b^*_1$ is the difference in the blue to yellow CIE $L^*a^*b^*$ color parameter. Translucency parameters (TP) were calculated using the following equation: $TP = [(L^*B - L^*W)^2 + (a^*B - a^*W)^2 +$

$$(b^*B - b^*W)^2]^{1/2}$$

where.

$L^*B - L^*W$ is the difference in the lightness parameter on black backing minus white backing from CIE $L^*a^*b^*$ color parameters.

$a^*B - a^*W$ is the difference in the red-green parameter on black backing minus white backing from CIE $L^*a^*b^*$ color parameters.

$b^*B - b^*W$ is the difference in the blue-yellow parameter on black backing minus white backing from CIE $L^*a^*b^*$ color parameters.

CIE L^* , a^* , and b^* were calculated and translucency parameters (TPs) were calculated for each specimen using D65 illumination with the specular component excluded. Means for TPD65 were determined for each group and compared between each group. The data were analyzed by two-way repeated-measures ANOVA with posthoc Tukey HSD ($\alpha = 0.05$) (SigmaPlot, Inpixon, Palo Alto, CA, USA).

Results: The complete staining and cleansing results data for TP are presented in Table 1 for DuraFlex and Table 2 for TCS. In addition, the overall change in translucency parameter (ΔTP) from baseline to cleansing data are included in both tables as well. Data revealed TP at baseline for TCS demonstrated greater overall translucency than DuraFlex. Both DuraFlex and TCS had slightly less than a 10% loss in translucency after staining. Whereas, based on two-way repeated-measures ANOVA after staining and use of either denture cleanser restored their respective initial translucency ($P = 0.130$) on both materials.

A significant decrease in TP occurred for TCS after staining for 20 days ($P < 0.001$), between 20 days and 40 days ($P < 0.001$), but not for DuraFlex ($P = 0.875$) across all staining treatments. DuraFlex alternatively had a significant transition in TP during the wine staining ($P < 0.001$). TCS Fresh cleaner induced a greater recovery of translucency when used on TCS ($P = 0.005$) material than TCS cleansed with Polident ($P = 0.130$).

DuraFlex cleansed with TCS Fresh only made a significant change in wine staining ($P < 0.001$). Polident cleanser on wine stained DuraFlex was not significant ($P = 0.059$).

Overall changes in ΔTP s were not significant ($P = 0.699$) between both cleansers and baseline time points.

Discussion: In this study, two flexible denture base materials (DuraFlex and TCS) were used to evaluate the change in translucency caused by three commonly consumed beverages (coffee, cola, and red wine) with DI water as a control. TCS is a polyamide resin developed from a type of nylon material, with 99.9% of its content consisting of nylon 12.⁷ DuraFlex is a polyolefin thermoplastic polymer used in the past for medical products because it is inert, strong, and resistant to numerous chemical solvents, bases, and acids. The water absorption rate of DuraFlex has been reported in marketing literature to be many times lower than nylon making DuraFlex partials extremely more stain and odor resistant.^{5,8} Both flexible materials are also advertised to have natural translucency, assuring positive esthetics resulting in greater patient acceptance.⁹

In this study, TCS demonstrated the most translucency change of the two materials. Coffee and wine were the strongest staining solutions. Staining in TCS is perhaps related to water sorption. This study may help improve recommendations for the home care of dentures and FRPDs, as well as FRPD performance and appearance.

In both denture base materials, color alterations can occur due to intrinsic or extrinsic factors. Intrinsic factors include discoloration of material due to differences in the polymer structure of each material. Extrinsic factors such as absorption and adsorption of substances may also lead to discoloration.

TCS is a polyamide resin with high water sorption values because water absorption happens among the molecular chains. This is due to the hydrophilic nature of the numerous amide bonds forming the chain of the polyamide resin. It is believed that the higher the amide group concentration, the greater the amount of water sorption.¹⁰ A previous study¹¹ reported that staining occurred due to the physical penetration of pigments between the molecular lattices or the adsorption of pigments on specimen surfaces. This could lead to a higher degree of staining in the nylon materials. The polyamide material also contains auxochromes which, when combined with chromophores and free radicals in solution, may result in staining.¹⁰ DuraFlex has a different chemical composition than TCS. It is a thermoplastic polyolefin (TPO) polymer and reportedly the water absorption rate is several times lower than nylon making it more resistant to staining.¹² TPO is a trade name that refers to a polymer/filler blend.¹³ The primary ingredient in the composition of DuraFlex is an ethylene-propylene copolymer.¹⁴ Fillers are added to improve the desired characteristics of the material although the exact fillers are not listed on the DuraFlex material safety data sheet. TPOs have also been used in industrial applications such as roofing and stadium seating due to their low water absorption rate.

Coffee, cola, and red wine were used because they are commonly consumed and have the ability to stain. Red wine contains chromogens and tannins and is known for intraoral staining.¹⁵ Chromogens are any substance found in organic fluids that form colored compounds when oxidized. Tannins are polyphenols that give the wine its dry taste. The alcohol content (10% alcohol by volume), as well as a low pH (approximately 3.7), seems significant in affecting the color stability in nylon denture base resins. One study,¹⁶ reported that the acidic pH may affect the material structure and that alcohol increases staining by softening the resin matrix.

Coffee is rich in chromogens and acids.¹⁷ The stainability of polymers by coffee has

been attributed to the presence of yellow colorants³ along with tannic acid which is especially responsible for staining.¹⁸ These colorants are both absorbed and adsorbed by the denture base material.

Cola is acidic, chromogen-rich, and can cause significant staining.¹⁸ The color of cola comes from the addition of caramel. Caramel is made by heating sugar in the presence of alkali or mineral acid. Of the beverages used, cola had the lowest pH and potentially produce greater damage to the surface integrity of the specimens. The color changes were instrumentally assessed using the spectrophotometer. The values produced by the instrument are important to give a quantitative assessment of the chromatic changes. However, the quantitative assessment of color change is meaningless unless it is determined how much visual color change is perceptible to the patient and how much color change is clinically acceptable to the patient. Since these levels are often subjective and will vary from patient to patient, there have been attempts in research to quantify these levels based on ΔE . They are referred to as the perceptibility threshold and acceptability threshold.¹⁹ A clinical review¹⁹ concluded that more than half the color studies in the dental literature used a perceptibility threshold of $\Delta E=1$ and one-third of the studies refer to $\Delta E=3.7$ as the threshold at which 50% of the observers accepted the color difference. Based on these thresholds our results indicated that the color change that occurred in TCS would be perceived by most patients.

If an FRDP is designed such that flexible clasps are placed on anterior teeth, the base material may be more visible than usual. Since the use of flexible denture base materials is often chosen based on the desire for optimum esthetics then discoloration and a loss of translucency may have a detrimental effect on esthetics.

Clinicians should advise their patients that the use of coffee, cola, and red wine can cause staining and a decrease in the translucency of the prosthesis. If these beverages are consumed while wearing the prosthesis, then strict home cleaning procedures should be followed including daily brushing with a soft-bristled brush

and a mild detergent. The daily use of a denture cleanser is also recommended.

Certain factors in this study make it difficult to compare the laboratory results obtained with those results that might be obtained under clinical circumstances. In this study, the specimens were not thermocycled or cleansed with denture cleansers during the staining process. Also, all specimens and beverages were maintained at 22°C (room temperature) rather than 37°C (intraoral temperature). These factors may alter the data and can be incorporated into future projects.

Denture cleansers are used for a variety of reasons including removing stains caused by food and drink. They are the main method of cleaning removable prostheses for elderly patients or those with limited neuromuscular skills. They are often classified by their chemical composition which can include enzymes, alkaline hypochlorite, acids, disinfectants, and alkaline peroxides.²⁰

The composition of Polident denture cleanser tablets according to the safety data sheet is as follows: citric acid 20%, sodium bicarbonate 11%, sodium perborate monohydrate 10%, potassium peroxymonosulfate 4.3%, non-hazardous ingredients 54.7%. Each component of the cleanser has a specific mode of action in the cleansing process. Citric acid and sodium carbonate react to form carbon dioxide causing mechanical cleansing. Sodium perborate monohydrate and potassium peroxymonosulfate are effective bleaching agents and disinfectants. The manufacturer of TCS concentrated appliance cleaner does not disclose the ingredients on the safety data sheet or on the company website. It is recommended by the manufacturer to use this cleanser for TCS flexible partial dentures.

Conclusion: The results of this study indicate that both cleansing agents were effective in removing stains produced by the different liquids. In this study, translucency parameters increased the most for TCS denture base material cleansed in TCS Fresh cleanser. There was not a significant difference when DuraFlex was cleansed with either solution.

Within the limitations of this study, it was noted that TCS was more translucent than DuraFlex, DuraFlex translucency was less affected by staining than TCS, TCS denture cleanser was more effective in recovering translucency when used with TCS material, and the difference in

translucency when cleaning DuraFlex with Polident and TCS was negligible. Further studies should determine the possible effect on the physical properties of the denture base materials that might be caused by the denture cleansers.

Acknowledgments: The authors thank Oral Arts Dental Laboratory for fabricating the DuraFlex and TCS specimens.

Disclosure statement: The authors declared no conflict of interest. This project was supported in part by The University of Tennessee Health Science Center College of Dentistry Alumni Endowment Fund and the Tennessee

Dental Association Foundation. Dr. Umsted is Associate Professor, Department of Prosthodontics, Dr. Dozier was a dental student and is currently in private practice in Nashville, Tennessee, USA; Dr. Ragain is Professor and Dean, and Mr. Morrow is a Senior Research Specialist, Department of Bioscience Research, and Dr. Garcia-Godoy is Professor, Department of Bioscience Research, College of Dentistry, The University of Tennessee Health Science Center, Memphis, Tennessee, USA and Adjunct Faculty, The Forsyth Institute, Cambridge, Massachusetts, USA.

References:

- Christensen, G.J. *Flexible, Removable partial Dentures-Good or Bad? Clinicians Report* 4(1) 2011.
- DuraFlex <https://nationaldentex.com/ndxkeller/products/dentures-partials/partial/>; 2021[accessed 15 November 2021].
- Wieckiewicz M, Opitz V, Richter G, Boenig KW. *Physical properties of polyamide-12 versus PMMA denture base material. Biomed Res Int* 2014; DOI:10.1155/2014/150298.
- Ragain JC Jr, Johnston WM 2001. *Accuracy of Kubelka-Munk reflectance theory applied to human dentin and enamel. J Dent Res* 2001;80:449-52.
- Johnston WM, Hesse NS, Davis BK, Seghi RR. *Analysis of edge-losses in reflectance measurements of pigmented maxillofacial elastomer. J Dent Res* 1996;75:752-60.
- How does a spectrophotometer work? CM-5 - Konica Minolta Sensing <https://www.youtube.com/watch?v=3SATP74kDAY>; 2015[accessed 20 March 2021]
- TCS safety data sheet <https://tcsdentalinc.com/wp-content/uploads/2020/07/SDS-iFlex-by-TCS-2015.pdf>; 2015[accessed 15 March 2021]
- The Myerson Company Limited. *Safety Data Sheet. Product Name: DuraFlex* <https://www.myersontooth.com/duraflex/>; 2011[accessed 15 November 2021].
- About DuraFlex <http://www.buckleyhutton.com/#!DuraFlex/c1krw>; 2015[accessed 20 March 2021]
- Takabayashi Y. *Characteristics of denture thermoplastic resins for non-metal clasp dentures. Dent Mater J* 2010;29:353-61
- Ueda K, Takeda T, Ichihata T, Kobayashi I, Nakamura T, Morita E, Gotoh H, Umi T, Satoh Y, Ohki K. *Studies on the coloration of the denture base. Part 1. On the influence of surface roughness and favorite taste. J Jpn Prosthodont Soc* 1985;29:85-93.
- DuraFlex Flexible Partial Dentures. <http://www.dentalartslab.com/products-services/removable-partial-dentures/duraflex-flexible-partial-dentures/>; 2015[accessed 15 November 2021]
- Thermoplastic polyolefin. http://en.wikipedia.org/wiki/Thermoplastic_olefin; 2015 [accessed 15 November 2021]
- The Myerson Company Limited. *Safety Data Sheet. Product Name: DuraFlex.* <https://www.myersontooth.com/duraflex/>; 2011[accessed 15 November 2021].
- Foods and Habits That Stain Your Teeth. <https://www.webmd.com/oral-health/features/foods-stain-teeth-feature>; 2015[accessed 15 November 2021].
- Bagheri R, Burrow MF, Tyas M. *Influence of food-simulating solutions and surface finish on susceptibility to staining of aesthetic restorative materials. J Dent* 2005;33:389-98.
- Douglas RD, Steinhauer TJ, Wee AG. *Intraoral determination of the tolerance of dentists for perceptibility and acceptability of shade mismatch. J Prosthet Dent* 2007;97:200-8.
- Guler AU, Yilmaz F, Kulunk T, Guler E, Kurt S. *Effects of different drinks on stainability of resin composite provisional restorative materials. J Prosthet Dent* 2005;94:118-24.
- Khashayar G, Bain PA, Salari S, Dozic A, Kleverlaan CJ, Feilzer AJ. *Perceptibility and acceptability thresholds for color differences in dentistry. J Dent* 2014;42:637-44.
- Durkan R, Ayaz EA, Bagis B, Gurbuz A, Ozturk N, Korkmaz FM. *Comparative effects of denture cleansers on physical properties of polyamide and polymethyl methacrylate-based polymers. Dent Mater J* 2013;32:367-75.

Table 1 & 2. Translucency parameters (TP) in color units for staining, cleansing, and overall change in TCS specimens.

TABLE 1

Solution	Cleanser	Baseline	20 days staining	40 days staining	Cleanser	ΔTP overall
Coffee	Polident	40.5(1.5) ^a	37.9(1.8) ^{a, b, c}	39.6(1.7) ^b	40.6(2.1) ^c	0.1(0.7)
	TCS DC	38.9(1.0) ^a	36.1(1.6) ^{a, b, c}	39.2(1.4) ^b	39.0(1.0) ^c	0.1(0.3)
Cola	Polident	39.8(2.5) ^a	38.3(2.2) ^{a, b}	39.7(2.8) ^{b, B}	39.6(3.0)	-0.2(0.8)
	TCS DC	40.2(2.0) ^a	37.9(2.1) ^{a, b, c}	40.0(2.2) ^{b, A}	39.5(2.1) ^c	-0.7(0.4)
Wine	Polident	40.1(2.4) ^a	36.3(3.5) ^a	34.3(2.9) ^{a, b, A, B}	37.4(2.2) ^{a, b}	-2.7(1.2)
	TCS DC	39.8(2.5) ^a	35.6(1.1) ^{a, b}	36.6(2.2) ^{a, b}	38.2(2.4) ^{a, b}	-1.6(0.7)
Water	Polident	39.2(1.1) ^a	37.1(1.7) ^{a, b, c}	39.2(1.1) ^b	40.1(1.6) ^c	1.0(0.8)
	TCS DC	39.5(0.7) ^a	37.4(1.2) ^{a, b, c}	39.4(0.9) ^b	40.0(1.0) ^c	0.4(0.4)

TABLE 2

Solution	Cleanser	Baseline	20 days staining	40 days staining	Cleanser	ΔTP overall
Coffee	Polident	40.5(1.5) ^a	37.9(1.8) ^{a, b, c}	39.6(1.7) ^b	40.6(2.1) ^c	0.1(0.7)
	TCS DC	38.9(1.0) ^a	36.1(1.6) ^{a, b, c}	39.2(1.4) ^b	39.0(1.0) ^c	0.1(0.3)
Cola	Polident	39.8(2.5) ^a	38.3(2.2) ^{a, b}	39.7(2.8) ^{b, B}	39.6(3.0)	-0.2(0.8)
	TCS DC	40.2(2.0) ^a	37.9(2.1) ^{a, b, c}	40.0(2.2) ^{b, A}	39.5(2.1) ^c	-0.7(0.4)
Wine	Polident	40.1(2.4) ^a	36.3(3.5) ^a	34.3(2.9) ^{a, b, A, B}	37.4(2.2) ^{a, b}	-2.7(1.2)
	TCS DC	39.8(2.5) ^a	35.6(1.1) ^{a, b}	36.6(2.2) ^{a, b}	38.2(2.4) ^{a, b}	-1.6(0.7)
Water	Polident	39.2(1.1) ^a	37.1(1.7) ^{a, b, c}	39.2(1.1) ^b	40.1(1.6) ^c	1.0(0.8)
	TCS DC	39.5(0.7) ^a	37.4(1.2) ^{a, b, c}	39.4(0.9) ^b	40.0(1.0) ^c	0.4(0.4)

Table 2. Legend:

Within rows, means with same lower-case superscripts letters indicate statistically significantly difference ($P < 0.05$) between time points for treatments groups. Within columns, means with same upper-case superscripts letters indicate statistically significantly difference ($P < 0.05$) between within time points.

Translucency stability of two flexible denture base materials after staining and exposure to cleansing agents

Publication date: Fall 2022. Expiration date: Fall 2024.

Objectives:

1. to determine which was most translucent at baseline between Duraflex (thermoplastic polymer) and TCS (nylon)
2. to determine the change in translucency of Duraflex and TCS after immersion in different beverages
- 3 to determine the effectiveness of cleansing with two different denture cleansers

1. What is the primary material of choice for complete dentures and removable partial denture bases?

- a. polymethylmethacrylate (PMMA)
- b. nylon
- c. polyolefin thermoplastic polymer
- d. chromium cobalt

2. What is one of the main advantages of flexible removable partial dentures?

- a. resistance to staining
- b. highly esthetic due to translucency
- c. materials are well researched
- d. physical properties don't degrade

3. What technique is used to fabricate flexible partial dentures in the laboratory?

- a. 3D printing
- b. subtractive milling
- c. closed-flask injection
- d. compression molding

4. Which is a biomedical instrument that measures the amount of light absorbed by a specimen?

- a. centrifuge
- b. instron
- c. spectrophotometer
- d. boley guage

5. Which material is a polyolefin thermoplastic polymer?:

- a. TCS
- b. Valplast
- c. PMMA
- d. Duraflex

6. How will the use of coffee, cola, and red wine affect the properties of a flexible removable partial denture?

- a. decrease in translucency
- b. increase in strength
- c. decrease in strength
- d. increase in color stability

7. Which individual component is present in the greatest percentage in Polident Denture Cleanser Tablets?

- a. sodium bicarbonate
- b. citric acid
- c. sodium perborate monohydrate
- d. potassium peroxymonosulfate

8. Within the limitations of this study which statement is true?

- a. Duraflex is more translucent than TCS
- b. Polident denture tablets are always more effective than TCS concentrated denture cleaner
- c. Duraflex translucency is less affected by staining than TCS
- d. nylon absorbs less water than Duraflex

1. Circle the correct answer on the exam and complete the form below;
2. Mail, along with your check or credit card payment, to: Tennessee Dental Association, 660 Bakers Bridge Ave., Suite 300, Franklin, TN 37067 or fax to (615) 628-0214.

Date: _____ (Credit is granted, upon successful completion of the exam, in the year materials are read and the exam submitted.)

- TDA Member Dentist: \$25.00
 Hygienist: \$25.00
 Registered Assistant: \$25.00
 Non-Member Dentist: \$55.00

Name: _____

If dentist, ADA ID Number: _____ District: _____

Address: _____

City/State/Zip: _____

Daytime Phone Number : _____ (_____)

Enclosed is my fee of \$ _____ payable to TDA, via check # _____ -or- Process: Mastercard Visa

Name as it appears on the card: _____

Card #: _____ Exp. Date: _____ CVV2: _____
(3 digit code on back of card following the card number)

Signature of Cardholder: _____

You will be notified by mail of your result and credit award. That certificate should be retained in your continuing education file. For TDA member dentists, ACE program credits will automatically be recorded.

GINGIVAL ENLARGEMENT IN PEDIATRIC PATIENT

with Prolonged Retention of Primary Teeth: A case report

AUTHORS

Sarah Alouani¹
Cimara Fortes Ferreira, DDS, MSc, PhD,
MDS2
Alicia Johnson³

CORRESPONDING AUTHOR

Cimara Fortes Ferreira DDS, MSc, PhD, MSD.
Department of Periodontology -
UTHSC College of Dentistry - Dunn
Building, Suite S502
875 Union Ave. Memphis TN 38163
Email: cimarafortes@hotmail.com
Phone: 954 579 9545
Fax: 901 448 6751

AUTHOR CONTRIBUTION

Sarah Alouani: Performed treatment planning, and extractions, and revised the article.

Cimara Ferreira: Performed periodontal procedures, and treatment planning, and prepared the article.

Alicia Johnson: Assisted in surgical procedures and revised the article.

There are several treatment options available including the use of Cognitive Behavioral Intervention for Tics (CBIT)⁴, deep brain stimulation (DBS) which is not FDA approved for use in the United States⁵, and prescription drugs like Clonidine (Catapres), Topiramate (Topamax) and Pimozide (Orap). Unfortunately, the medication route can have severe adverse side effects, especially for children. Therefore, this route should be avoided when treating children. CBIT can provide patients with

ABSTRACT

Prolonged retention of primary teeth can cause a multitude of long-term complications. These can range from teeth crowding to the development of periodontal diseases. The higher the severity of the crowding of permanent and primary teeth, the higher the functional and esthetic compromise and the difficulty in maintaining adequate oral hygiene, increasing the likelihood of acquiring the periodontal disease. The present case consists of prolonged retention of primary mandibular anterior teeth in a 12-year-old male with a periodontal diagnosis of severe GO. The primary teeth were extracted and a gingivectomy was performed to remove excess tissue and allow permanent teeth to erupt into a more ideal position, as well as allow for adequate oral hygiene, function, and esthetics.

Keywords: prolonged retention of primary teeth, gingival overgrowth, gingivectomy

CLINICAL RELEVANCE

Scientific Rationale: Gingival overgrowth (GP) in a pediatric patient with retained primary dentition can present a periodontal treatment challenge. Extraction of the primary dentition along with a gingivectomy procedure is proposed. This single intervention can improve the esthetics, occlusion, and oral hygiene, and aid in establishing a healthy periodontium.

Principal Findings: The gingivectomy allowed prompt treatment of the patient's GO and the extraction reduced crowding of the lower arch, both of which improve esthetics.

Practical Implications: The gingivectomy and extractions allowed the creation of

space around the mandibular anterior dentition that will allow the patient to perform more efficient oral hygiene.

INTRODUCTION

Gingival overgrowth (GO), also known as elephantiasis gingivae, hypertrophic gingivitis, gingival hyperplasia, or gingival hypertrophy, is defined as progressive normal-colored enlargement of the gingiva which partially or fully covers crowns of teeth¹. It can be induced by a vast range of factors or combinations of factors. Some examples include hereditary causes, drug-induced gingival fibromatosis, systemic disease, and in some cases are idiopathic². Some studies suggest that in certain circumstances, depending on the etiology, men are more susceptible to GO than women.

¹Dental Student, University of Tennessee Health Science Center College of Dentistry, Memphis, TN, USA.

²Associate Professor Periodontology, University of Tennessee Health Sciences College of Dentistry, Memphis, TN, USA.

³Dental Student, University of Tennessee Health Science Center College of Dentistry, Memphis, TN, USA.

or example, If the GO is secondary to nifedipine drug use or other calcium channel blockers, men are more likely to be affected because of the high incidence of CV disease in men³. Drugs known to cause GO include antiepileptic medications, immunosuppressants, or calcium-channel blockers². Some syndromes associated with GO in children include neurofibromatosis type I, Leukemia, Hodgkin's Lymphoma, Sweet-Like Syndrome, and Schinzel-Giedion Syndrome⁴. Other possibilities of causes of gingival enlargement, although rare in pediatric patients, can include granulomatous diseases such as Crohn's disease, Tuberculosis, leukemic infiltration, or other blood dyscrasias⁵.

There is also a genetic predisposition component to GO. Some patients on the previously listed drugs known to cause GO develop GO and some do not, depending on the nature of each individual's gingival fibroblasts⁶. The only genetic marker that has been investigated in drug-induced GO is HLA type; one study concluded that patients with HLA-DR1 are less likely to have GO whilst HLA-DR2 were more likely to express GO⁷. Some sources conclude it is more common in younger-aged males in the anterior gingiva, as seen in this case⁶. The pathophysiology of GO is complex, and oral hygiene further complicates this dilemma. It is unknown whether plaque aids in GO, or overgrown gingiva aid in the retention of plaque in deeper pockets⁸. Proposed histological behavior ranges from multiplication of normal fibroblasts with increased production of collagen with phenytoin, to an increase in epithelium without an increase in collagen as seen in histologic studies of patients on Cyclosporine⁹. On the cellular level, it has been found with most drugs inducing GO that they inhibit intracellular calcium ion influx⁹. Independent of the specific cause, GO can be a concern when it comes to esthetics, function, and the periodontium. It typically remains confined within the attached gingiva, but can extend beyond this to interfere with mastication, occlusion, and speech⁸. Retained primary teeth with a simultaneous eruption of permanent successors can cause GO, especially due to the difficulty in the ability to maintain proper oral hygiene³. One study also

states that the eruption of permanent teeth may accelerate gingival hyperplasia¹⁰. Idiopathic gingival enlargement at a young age, although rare, has been reported in an 11-year-old boy in the absence of permanent teeth¹¹. Another rare case of severe gingival enlargement without any medical or drug-related cause has been reported in a 12-year-old girl that was so significant she was unable to attend school due to the "ghastly appearance"¹¹. A case of inflammatory gingival enlargement was seen in a 10-year-old boy with vitamin C deficiency, which improved in one week after taking vitamin C supplements¹².

Management of GO involves eliminating etiological agents and if this is not successful, surgery field¹³. The main local factor associated with GO is plaque which can be modified by OHI, and systemic factors associated with GO should be investigated and modified as needed¹³. Surgical management of GO includes excisional biopsy, gingivectomy (laser, electric, scalpel), or periodontal flap surgery¹³. Recurrence is more common with surgical procedures than with management of etiologic factors¹³, thus highlighting the importance of proper diagnosis. This case report describes the dental management of a case of retained deciduous dentition with crowding and gingival enlargement in a 12-year-old male.

CASE REPORT

A 12-year-old African American male presented with a chief complaint of "having two rows of teeth". Upon clinical evaluation, it was noted that he presented with primary teeth M-R as well as #23-26. Medical history indicated that the patient was taking Cetirizine 1mg as needed for eczema for the last 3 months.

The gingival tissues were severely overgrown, covering more than half the crowns of the permanent teeth (Figure 1), with severe subgingival calculus buildup. Probing depths were 5-6mm and tissue bled significantly upon light probing. A significant plaque score revealed the patient's poor oral hygiene. The gingival tissues were firm and fibrotic in nature (Figures 1-3). The possible periodontal diagnosis is plaque-induced GO or/associated with

anemia and other blood dyscrasias (leukemia, thrombocytopenia, or thrombocytopathy). For final diagnosis, a blood test would be necessary to rule out the systemic factor.

The patient and guardian were informed that the optimal treatment plan involved extraction of the remaining primary teeth #M-R and gingivectomy in the anterior mandible area. The patient was compliant and did not require sedation.

The patient was anesthetized via local infiltration of one carpule of 4% septocaine (1:100 000 epinephrine). Teeth #23-26 presented with significant amounts of calculus. A piezoelectric ultrasonic dental scaler was used to scale the teeth. Next, deciduous teeth #M-R were extracted with caution not to disturb the partially erupted subjacent permanent teeth #22 and 27 (Figures 4,5). Next, the tissues were thoroughly irrigated and air-dried in search of remnants of calculus.

After extraction of the deciduous teeth, gingivectomy was performed using an external bevel incision with a 15C blade to remove all excess tissue surrounding extracted teeth. Interproximally, an Orban knife was used to remove the incised papillary tissues (Figure 6,7) Next, all tissues were irrigated with saline solution. The patient and his parent were given post-operative instructions and scheduled for routine post-operative visits.

The patient returned for the post-op visit 4 weeks later. Gingiva healed and significantly reduced in size; however, new calculus buildup on mandibular anterior incisors (Figure 8). The lingual aspect of the mandibular anterior region 4-weeks post-op showed the presence of remaining marginal erythematous tissues (Figure 9). The patient acknowledged that he did not perform oral hygiene in the mandibular anterior area due to soreness in the gingiva. The anterior teeth were scaled using a Piezoelectric ultrasonic dental scaler (Figure 10,11). Oral hygiene instructions were re-emphasized to the patient, and he was placed on a 3-month hygiene recall. At the 6-month recall, note the presence of recurrence of gingival growth (Figure 12).

DISCUSSION

The gingival enlargement may become very severe that it may cover the teeth up to their occlusal surfaces^{14,15}. The most common side-effects related to the gingival lesions are diastemas, mispositioning of the teeth, and prolonged retention of primary teeth¹⁶, as well as the delayed eruption of permanent teeth.^{12, 17,18}

This case report shows prolonged retention of primary teeth in a 12-year-old African American male, resulting in an ectopic lingual eruption of the permanent mandibular incisors. The ectopic eruption is defined as a tooth erupting in an abnormal position or orientation¹⁹.

GO has been studied in children with sickle cell disease (SCD)²⁰. It is estimated that SCD affects approximately 100,000 Americans. About 1 in 13 Black or African-American babies is born with sickle cell trait²¹. The two important features of SCD are chronic hemolytic anemia and vaso-occlusion, resulting in ischemic tissue injury²⁰. In the present clinical case, a blood exam was not conducted to rule out the patient having sickle cell disease, which is prevalent in his race.

Retention of the primary teeth contributed to

significant gingival hyperplasia. Gingival hyperplasia can result in esthetic and functional problems²². Additionally, it can increase the risk of periodontal disease due to difficulty in performing thorough oral hygiene practices²³. The present case report shows the effects of extraction of primary teeth and gingivectomy to optimize esthetics, guide permanent teeth eruption in the proper position, and allow for adequate oral hygiene and function with a successful result at the 4-week post-op visit.

In the present case report, extraction of the mandibular anterior teeth and gingivectomy were conducted to provide the patient with an esthetic outcome and ensure ease of performing oral hygiene practices²⁴. Studies have shown that oral hygiene is impaired if crowding is not addressed²⁵. The literature shows that the degree of gingival enlargement does not appear to be related to oral hygiene or the amount of calculus present and that a correct physiologic contour of the marginal gingiva is more important to preventing recurrence²⁶. In the present study, GO was temporarily resolved using gingivectomy and adjustment of the bony contours to reduce high probing depths and

calculus build-up. Both extractions and gingivectomy using the external bevel incisions were successful in restoring the patient's esthetics and function in the area²⁷.

Recurrence of the gingival growth is common over varying periods. One report indicated that there is less chance of recurrence if the gingivectomy is delayed until the eruption of the permanent dentition²⁸. However, slight recurrence was seen after 20 months²⁹. In the present case report, 6 months after the gingivectomy procedure was executed, there is evidence of reoccurrence of gingival growth.

CONCLUSION

The present case shows successful treatment of prolonged retention of primary mandibular anterior teeth in a 12-year-old male with a periodontal diagnosis of severe GO by extraction of primary teeth and a gingivectomy to remove excess tissue and allow permanent teeth to erupt into a more ideal position, as well as allow for adequate oral hygiene, function, and esthetics.

References:

1. Gawron K, Lazarz-Bartyzel K, Potempa J, Chomyszyn-Gajewska M. Gingival fibromatosis: clinical, molecular and therapeutic issues. *Orphanet J Rare Dis* 2016;11:9.

2. Sharma S, Shahi AK, Prajapati VK, Singh B. Idiopathic gingival fibromatosis with massive gingival overgrowth: A rare case report. *J Indian Soc Periodontol* 2020;24:379-382.

3. Lai B, Muenzer J, Roberts MW. Idiopathic gingival hyperplasia: a case report with a 17-year followup. *Case Rep Dent* 2011;2011:986237.

4. Doufexi A, Mina M, Ioannidou E. Gingival overgrowth in children: epidemiology, pathogenesis, and complications. A literature review. *J Periodontol* 2005;76:3-10.

5. Pette GA, Siegel MA, Parker WB. Gingival enlargement. *J Am Dent Assoc* 2011;142:1265-1268.

6. Tungare S, Paranjpe AG. Drug Induced Gingival Overgrowth. In: *StatPearls*. Treasure Island (FL), 2022.

7. Seymour RA, Ellis JS, Thomason JM. Risk factors for drug-induced gingival overgrowth. *J Clin Periodontol* 2000;27:217-223.

8. Marshall RI, Bartold PM. Medication induced gingival overgrowth. *Oral Dis* 1998;4:130-151

9. Bharti V, Bansal C. Drug-induced gingival overgrowth: The nemesis of gingiva unravelled. *J Indian Soc Periodontol* 2013;17:182-187.

10. Han Gao J, Jun Liang, Xiaoxue Xia, Zhaoming Deng T, Zhaoqiang Zhang. Unusual clinical and histologic findings in a child with mixed dentition with hereditary gingival fibromatosis: a case report. *Translational pediatrics* 2020;9:74-80.

11. Kavvadia K, Pepelassi E, Alexandridis C, Arkadopoulou A, Polyzois G, Tossios K. Gingival fibromatosis and significant tooth eruption delay in an 11-year-old male: a 30-month follow-up. *Int J Paediatr Dent* 2005;15:294-302.

12. Katz J, Guelmann M, Barak S. Hereditary gingival fibromatosis with distinct dental, skeletal and developmental abnormalities. *Pediatr Dent* 2002;24:253-256.

13. Chesterman J, Beaumont J, Kellett M, Durey K. Gingival overgrowth: Part 2: management strategies. *Br Dent J* 2017;222:159-165.

14. Goldblatt J, Singer SL. Autosomal recessive gingival fibromatosis with distinctive facies. *Clin Genet* 1992;42:306-308.

15. Brown RS, Trejo PM, Weltman R, Pinero G. Treatment of a patient with hereditary gingival fibromatosis: a case report. *Spec Care Dentist* 1995;15:149-153.

16. Bittencourt LP, Campos V, Moliterno LF, Ribeiro DP, Sampaio RK. Hereditary gingival fibromatosis: review of the literature and a case report. *Quintessence Int* 2000;31:415-418.

17. Oikarinen K, Salo T, Kaar ML, Lahtela P, Altonen M. Hereditary gingival fibromatosis associated with growth hormone deficiency. *Br J Oral Maxillofac Surg* 1990;28:335-339.

18. Wynne SE, Aldred MJ, Bartold PM. Hereditary gingival fibromatosis associated with hearing loss and supernumerary teeth—a new syndrome. *J Periodontol* 1995;66:75-79.

19. Mucedero M, Rozzi M, Cardoni G, Ricchiuti MR, Cozza P. Dentoskeletal features in individuals with ectopic eruption of the permanent maxillary first molar. *Korean J Orthod* 2015;45:190-197.

20. Tonguc MO, Unal S, Arpaci RB. Gingival enlargement in children with sickle cell disease. *J Oral Sci* 2018;60:105-114.

21. U.S. Department of Health & Human Services. Data & Statistics on Sickle Cell Disease. Available at: <https://www.cdc.gov/ncbddd/sicklecell/data.html>. Accessed: 03/31/2022, 2022.

22. Brierley DJ, Crane H, Hunter KD. Lumps and Bumps of the Gingiva: A Pathological Miscellany. *Head Neck Pathol* 2019;13:103-113.

23. Omori K, Hanayama Y, Naruishi K, et al. Gingival overgrowth caused by vitamin C deficiency associated with metabolic syndrome and severe periodontal infection: a case report. *Clin Case Rep* 2014;2:286-295.

24. Ramer M, Marrone J, Stahl B, Burakoff R. Hereditary gingival fibromatosis: identification, treatment, control. *J Am Dent Assoc* 1996;127:493-495.

25. Kolawole KA, Folayan MO. Association between malocclusion, caries and oral hygiene in children 6 to 12 years old resident in suburban Nigeria. *BMC Oral Health* 2019;19:262.

26. Emerson TG. Hereditary Gingival Hyperplasia. A Family Pedigree of Four Generations. *Oral Surg Oral Med Oral Pathol* 1965;19:1-9.

27. Bansal A, Narang S, Sowmya K, Sehgal N. Treatment and two-year follow-up of a patient with hereditary gingival fibromatosis. *J Indian Soc Periodontol* 2011;15:406-409.

28. James PL, Prasad SV. Gingival fibromatosis: report of case. *Journal of oral surgery* 1971;29:55-59.

29. Baptista IP. Hereditary gingival fibromatosis: a case report. *J Clin Periodontol* 2002;29:871-874.

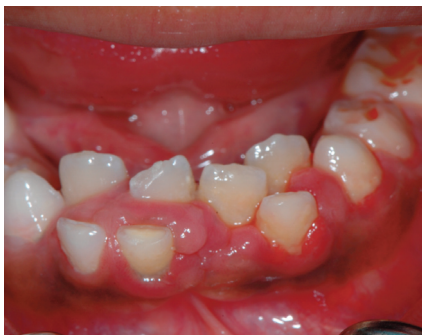

Figure 1 Frontal view of the mandibular anterior region. Note the retained primary teeth and unesthetic smile. Note the edematous gingival tissues in between the two layers of teeth in the anterior mandibular region.

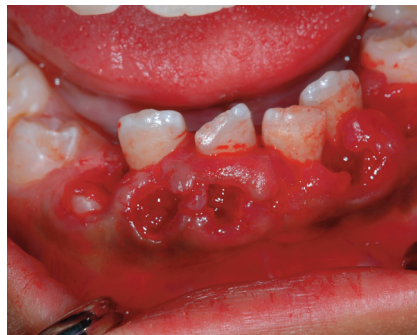

Figure 5 Frontal view of the mandibular anterior ridge after extraction of retained deciduous teeth. Note Overgrown gingiva covering >50% crowns of permanent incisors.

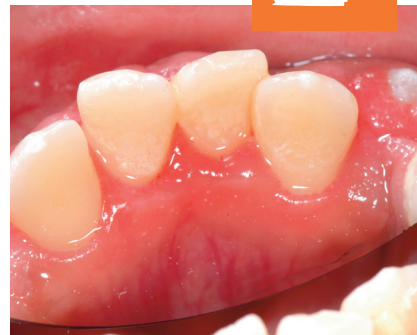

Figure 9 Lingual view of mandibular anterior ridge 4 weeks post-op. Note remaining marginal erythematous tissues.

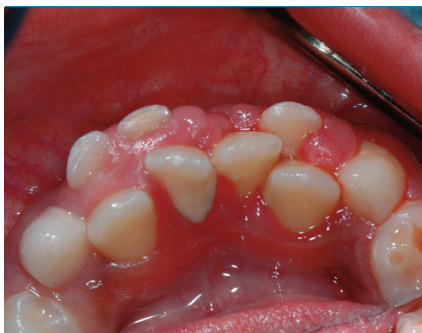

Figure 2 Occlusal view of mandibular anterior ridge. Note the edematous gingival tissues in between the two layers of teeth in the anterior mandibular region.

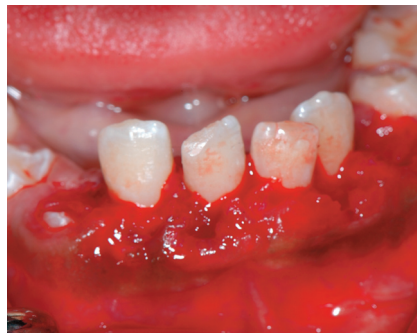

Figure 6 Frontal view of the anterior ridge after gingivectomy performed from X to X.

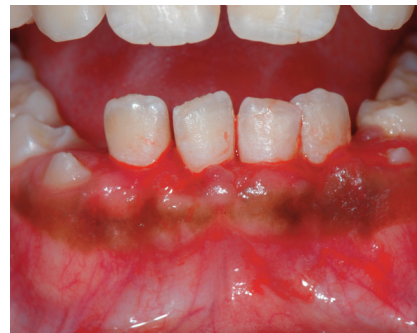

Figure 10 Frontal view of the mandibular anterior region after scaling permanent incisors at the 4-week post-op visit. Note that there is still the presence of residual alveolar ridge of the previously retained teeth.

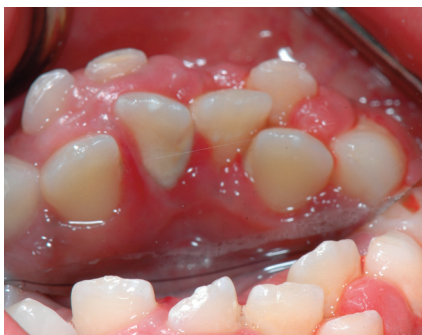

Figure 3 Lingual view of mandibular anterior ridge. Note the edematous gingival tissues in the buccal aspect and the erythematous gingival tissues in the lingual aspect of the mandibular anterior region.

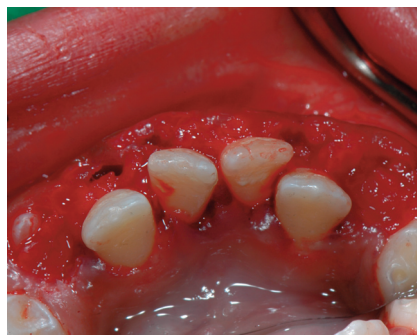

Figure 7 Occlusal view of the mandibular anterior ridge after gingivectomy performed.

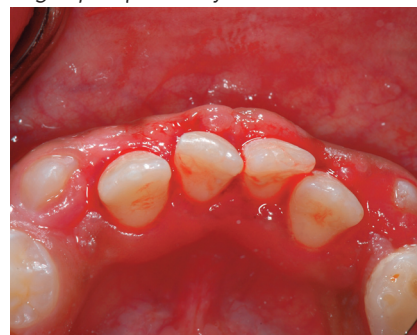

Figure 11 Lingual view of the mandibular anterior region after scaling at 4 weeks post-op

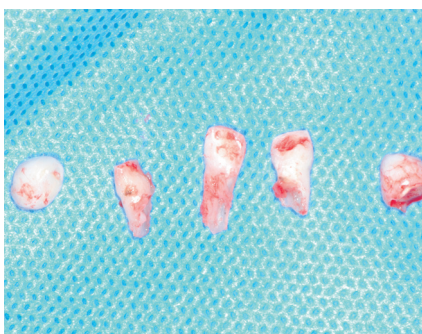


Figure 4 Primary teeth #M, N, P, Q, R after extraction

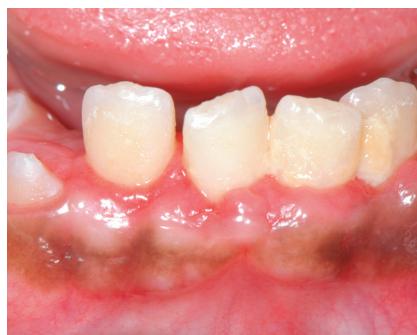

Figure 8 Frontal view of mandibular anterior ridge 4 weeks post-op. Note the presence of severe microbial plaque and calculus buildup on the buccal aspect of the mandibular incisors. In addition, the gingival tissues are erythematous and edematous, and they show rolled margins.

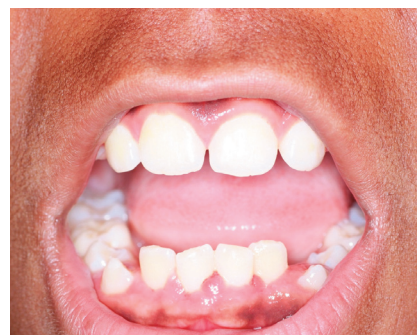

Figure 12 Frontal view of the mandibular anterior ridge after scaling permanent incisors at the 6-month post-op visit. Note the reduction of the residual alveolar ridge of the previously retained teeth.

Gingival Enlargement in Pediatric Patient with Prolonged Retention of Primary Teeth: A case report

Publication date: Fall 2022. Expiration date: Fall 2024.

Objectives:

- Description of a case of gingival overgrowth in a 12-year-old African American with retained primary lower incisors
- Identifying possible underlying causes of this gingival overgrowth according to the literature and similar cases
- Consequences and implications of gingival overgrowth associated with retained primary incisors
- Treatment options for gingival overgrowth associated with retained primary incisors
- Whether or not the treatment option of extractions/gingivectomy is a successful method for this case and possibly similar cases

1. All the following are possible systemic causes of gingival overgrowth except:

- a. Sickle cell anemia
- b. Hodgkin's Lymphoma
- c. Leukemia
- d. Hyperthyroidism

2. Which of the following classes of drugs is associated with evidence of gingival overgrowth?

- a. Beta-Blockers
- b. Calcium Channel Blockers
- c. ACE Inhibitors
- d. Loop Diuretics

3. According to the literature, gingival overgrowth is more prevalent in men than women. Gingival overgrowth typically remains confined to the attached gingiva.

- a. The first statement is true, the second is false
- b. The second statement is true, the first statement is false
- c. Both statements are true
- d. Both statements are false

4. In this case, report, which is the primary treatment method was used to resolve the gingival overgrowth?

- a. Laser-assisted gingivectomy
- b. Extractions followed by external bevel incision gingivectomy
- c. Scaling and root planing
- d. Periodontal surgery

5. Literature shows that the degree of gingival enlargement is primarily associated with what?

- a. Lack of proper gingival contour
- b. Patient age
- c. Probing depths
- d. Amount of calculus buildup

6. Resolution of gingival overgrowth can allow for:

- a. Better function
- b. Better esthetics
- c. Better oral hygiene/access to the area
- d. All the above

1. Circle the correct answer on the exam and complete the form below;
2. Mail, along with your check or credit card payment, to: Tennessee Dental Association, 660 Bakers Bridge Ave., Suite 300, Franklin, TN 37067 or fax to (615) 628-0214.

Date: _____ (Credit is granted, upon successful completion of the exam, in the year materials are read and the exam submitted.)

- TDA Member Dentist: \$25.00 Hygienist: \$25.00 Registered Assistant: \$25.00 Non-Member Dentist: \$55.00

Name: _____

If dentist, ADA ID Number: _____ District: _____

Address: _____

City/State/Zip: _____

Daytime Phone Number : _____ (_____)

Enclosed is my fee of \$ _____ payable to TDA, via check # _____ -or- Process: Mastercard Visa

Name as it appears on the card: _____

Card #: _____ Exp. Date: _____ CV2: _____
(3 digit code on back of card following the card number)

Signature of Cardholder: _____

You will be notified by mail of your result and credit award. That certificate should be retained in your continuing education file. For TDA member dentists, ACE program credits will automatically be recorded.

ANTERIOR MAXILLARY SWELLING IN A 69-YEAR-OLD FEMALE: *A Case Report*

David R. Lifferth, DMD, K. Mark Anderson, DDS, Christopher W. Holladay, DMD, Jon A. Howell

INTRODUCTION

In the practice of Oral and Maxillofacial surgery, it is crucial to appropriately recognize and manage pathologic entities. Although most tumors in the head and neck region are benign, collateral damage from expansive growth of these lesions can occur. It is also critical to rule out cases of malignancy. Clinical examination, radiographic imaging, and histologic analysis are necessary to construct a differential diagnosis, as well as the treatment of choice for the final diagnosis.

In this case report, we present an intraoral lesion with features common to several possible tumors. After clinical examination, CBCT imaging, biopsy, and histologic analysis, the patient was diagnosed with a pleomorphic adenoma. This case was unique in that these lesions do not typically present on the anterior hard palate. The lesion was surgically removed and stented with an acrylic plate for healing purposes.

CASE REPORT

A 69-year-old female presented to University Dental Practice at the University of Tennessee College of Dentistry with complaint of a growth on the anterior hard palatal area. The patient described the growth as non-painful and stated that it had been slowly enlarging for at least the past 15 years. Initial examination and evaluation of the patient revealed edentulous maxilla with a 3 cm non-ulcerated swelling of the anterior left palate. The lesion was somewhat fluctuant upon palpation and non-tender. A CBCT cone beam was taken which identified the anterior left hard palate soft tissue lesion to be 2.8x3.3x1.9 cm (w, l, h) in size with non-invasive expansion into the alveolar bone. The lesion did not show any apparent communication with the nasopalatine duct.

ABSTRACT

A 69-year-old female presented to the University of Tennessee College of Dentistry with complaint of a growth on the anterior hard palate. Clinical examination and CBCT imaging provided a differential diagnosis. Incisional biopsy was performed, and the specimen sent to the University of Tennessee oral pathologic diagnostic laboratory for diagnosis. Microscopic analysis revealed a mixture of chondroid material, myoepithelial cells, and ductal epithelial cells. These findings, along with clinical presentation and CBCT imaging, were consistent with a diagnosis of pleomorphic adenoma. Surgical work up was performed for complete excision and impressions were taken preoperatively in the clinic for fabrication of a post-surgical stent. The patient was taken to the local hospital for ambulatory surgery and placement of the palatal stent, which. This case represents a common benign oral pathologic lesion in an uncommon location. It was critical in this case to rule out other possible diagnoses, and therefore extensive discussion on features common to other pathologic lesions were documented.

The patient's medical history was significant for Sickle Cell Trait, HTN, CHF, and seizure disorder (2 seizures w/in the last year and was placed on anti-seizure medication). She was taking carvedilol, spironolactone, lisinopril, aspirin 81mg, levetiracetam, meclizine, tizanidine, budesonide and Ventolin. She also admitted to alcohol, marijuana, and cocaine use. She stopped smoking cigarettes 15 years prior.

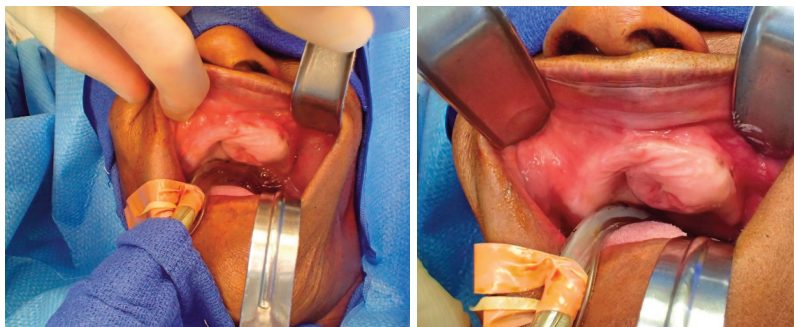


Figure 1a, 1b: Photographs showing size and location of lesion

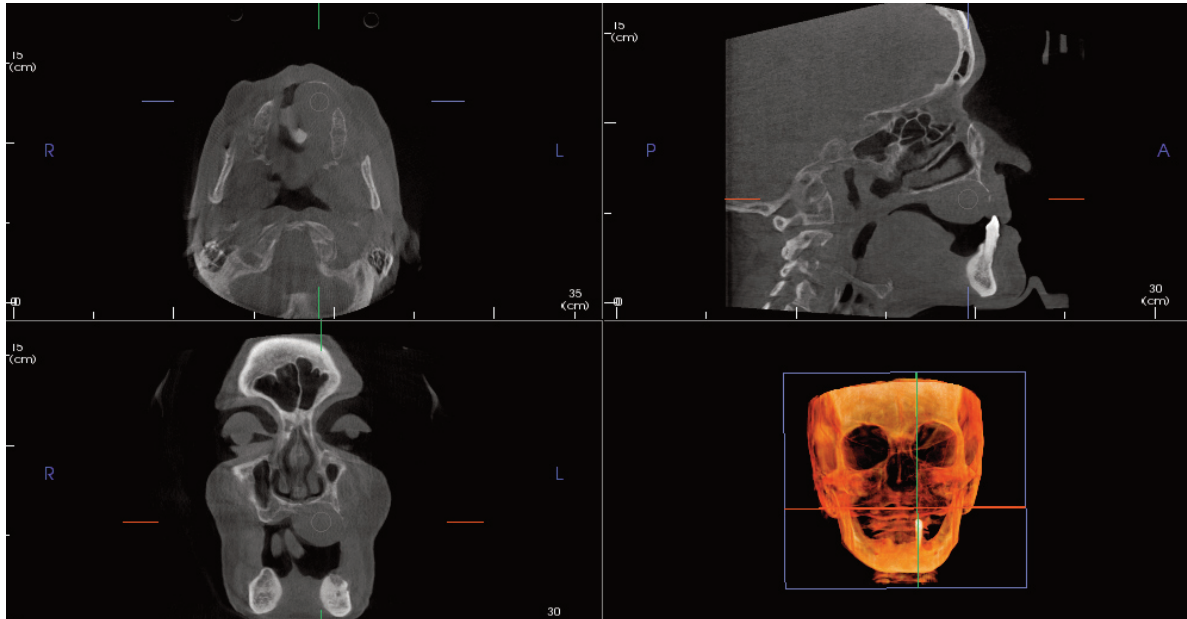


Figure 2: CBCT compilation of lesion on initial exam appointment

DIFFERENTIAL DIAGNOSIS

Based upon the clinical presentation and patient’s history, several potential diagnoses were considered and included odontogenic and non-odontogenic processes.

Odontogenic Keratocyst

While odontogenic keratocysts have a peak incidence in the 2nd and 3rd decades of life, they occur at all ages². Although they are twice as likely to occur in the mandible⁵, in the aging population, there is an increased likelihood that the lesion will occur in the anterior maxilla, specifically in the canine region. Bony resorption may include the cortex but at a much slower rate than the intermedullary trabecular bone. Histopathologically, the lining consists of a 6-8 cell layer of stratified squamous epithelium. The junction between the epithelium and underlying connective tissue is flat, with no rete ridge morphology and a hyperchromatic, palisaded basal layer. The luminal surface of the linings demonstrates flat parakeratotic cells¹. Often, small satellite cysts, cords, or islands of odontogenic epithelium may be seen within the fibrous wall¹.

Calcifying Odontogenic Cyst

Calcifying odontogenic cysts have a marked predilection for females and for occurrence in the anterior maxilla². These cysts can cause expansion and present as a firm, painless swelling. The radiographic presentation typically shows a well-defined, unilocular lucency in which calcifications may be seen. Extrasosseous calcifying odontogenic cysts account for 25% of all lesions in individuals older than 50 years old. While our patient’s radiograph did not show calcifications (figure 2), the location and the patient demographic would be consistent with an extrasosseous calcifying odontogenic cyst. Histologically, these cysts have a distinctive basal cell layer that consists of cuboidal to columnar cells². The cystic lining may be thin or thick. Ghost cells, or eosinophilic epithelial cells with degenerated nuclei, are a characteristic finding of calcifying odontogenic cysts.

Nasopalatine Duct Cyst

The nasopalatine duct cyst can occur at almost any age but is most common during the 4th to 6th decades of life¹. Oftentimes, these cysts are associated with swelling of the anterior maxilla, which may be fluctuant in nature. If these cysts

go unchecked or untreated, they may expand to produce a “through and through” lesion that resorbs the palatal and facial alveolar bone. Nasopalatine duct cysts can range in size from 6mm to 6cm. However, most lesions are within the 1.0-2.5cm size. Histologically, these lesions may be stratified squamous epithelium, pseudostratified columnar epithelium, or a combination of these. Usually, the cystic wall contains fibrous tissue and structures reflecting the anatomy of the area, including vessels, nerve bundles, fat and occasional mucous glands².

Pleomorphic Adenoma

Pleomorphic adenoma, also known as a mixed tumor and benign mixed tumor, is common among salivary gland tumors, making up 53-77% of parotid tumors, 44-68% of submandibular tumors, and 33-43% of minor salivary gland tumors¹. Pleomorphic adenomas have a strong predilection for the parotid region with 80% of all pleomorphic adenomas occurring at this site.

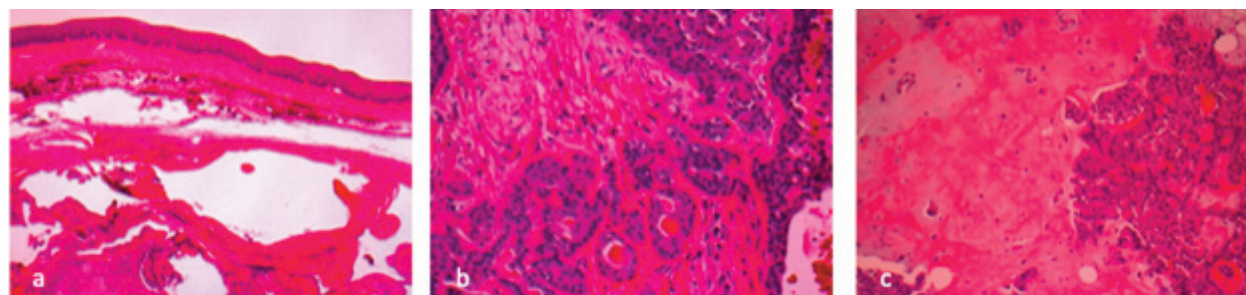


Figure 3: (a) Gross, low power specimen showing partial capsular lining (b) mixture of epithelial and myoepithelial cells (c) chondroid stroma

An additional 10% occur in the submandibular region and 10% occur intraorally. Among intraoral sites, the palate is most frequent (50%) usually off to one side of the midline, followed by upper lip (27%) and buccal mucosa (17%). Palatal tumors are almost always found on the posterolateral aspect¹. The clinical presentation usually reveals a rubbery firm on palpation, non-ulcerated mass that is pain-free. When a pleomorphic adenoma presents in the mucosa of the hard palate, the mass will seem to be fixed to the palate. Since the pleomorphic adenoma cannot invade bone, the overlying soft tissue becomes distended by the tumor mass and may eventuate in a cupped-out resorption of bone².

The histologic appearance of pleomorphic adenomas demonstrates encapsulated proliferation of ductal epithelial cells and myoepithelial cells in varying proportions. The cellular portion of the tumor may form a variety of patterns, including sheets, ribbons, or ductal configurations. Squamous cells and keratin pearls may or may not be present². The stroma may vary from densely collagenous to a myxoid or chondroid appearance.

Ameloblastoma

The peripheral ameloblastoma, while not as common as the intraosseous variant, accounts for about 1% to 10% of all ameloblastomas¹. These lesions typically present as a painless, nonulcerated, sessile or pedunculated gingival or alveolar mucosal lesion. The underlying superficial alveolar bone may become slightly eroded but significant bone involvement does not occur¹.

The histologic appearance is similar to the intraosseous form of the tumor, likely arising from the rests of dental lamina. Islands of ameloblastic epithelium can be found occupying the lamina propria

underneath the surface epithelium. Treatment for this type of lesion consists of local surgical excision, with recurrence rates ranging from 15%-20%.

DIAGNOSIS AND TREATMENT

Incisional biopsy was performed under local anesthesia in the UTHSC Graduate Oral and Maxillofacial Surgery Clinic. Before biopsy was performed, the lesion was aspirated with an 18-gauge needle with no heme or discernible fluid returned. A #15 blade was then used to make an elliptical incision down to bone and the specimen was placed in neutral buffered formalin.

The specimen was then sent to University of Tennessee oral pathologic diagnostic laboratory for diagnosis. Hematoxylin and eosin stain was performed and demonstrated a partial capsule with a mixture of chondroid intercapsular material, myoepithelial cells, and ductal epithelial cells.

With the presence of the of the ductal epithelial and myoepithelial cells, the diagnosis of pleomorphic adenoma was made. Surgical work up was performed for complete excision and impressions were taken preoperatively in the clinic for fabrication of a post-surgical stent. The patient was taken to the local hospital for ambulatory surgery consisting of excision of the lesion with 5mm margins. The palatal stent, which was designed to allow for palatal coverage during the healing phase, was lined with COE-SOFT, and secured in place using mini screws.

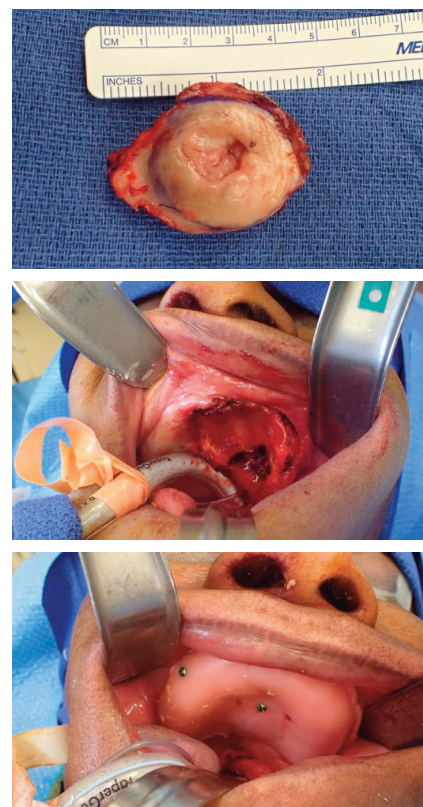


Figure 4: A surgical specimen after excision demonstrating dimensions. B, Intraoral site of lesion immediately after surgical excision was performed. C, Prefabricated, COE-SOFT lined retainer fixated in place with screws

DISCUSSION

Although pleomorphic adenoma is the most common benign salivary gland tumor, it has a high predilection for the parotid gland, with only 10% occurring intraorally. When found intraorally, it most commonly involves the minor salivary glands of the hard palate, upper lip, and buccal mucosa. Palatal lesions account for approximately 50% of these, typically on the lateral aspects. These minor salivary gland tumors present as slow-growing, painless submucosal masses. The more common palatal mixed tumors are located laterally and rarely cross the midline⁽⁴⁾.

Pleomorphic adenoma is best treated by complete surgical excision. Enucleation should be avoided due to the possibility of violating the capsule which could result in the seeding of the tumor bed. When these lesions occur on the hard palate, it is necessary to excise the tumor down to the periosteum while including the overlying mucosa. When adequate surgery is performed, the prognosis is excellent with a recurrence rate of less than 5%¹.

This lesion is unique as it was found in the anterior palate, mimicking the representation of an OKC in an elderly patient. OKCs of the anterior midline maxillary region can account for up to 13% of all OKCs. For unknown reasons,

this subset of keratocysts usually occurs in older individuals with a mean age of nearly 70 years¹. Given our patient profile, one might have expected the lesion to be an OKC. Thorough taking of medical history, history of present illness, and appropriate imaging and diagnostic tests help make distinctions between various lesions.

Different types of imaging modalities are useful in the initial diagnosis of lesions. MRI and CT will provide the most information with regards to soft tissue involvement if a salivary gland tumor is suspected. CT imaging is the modality of choice when determining bony involvement. Based on the CT imaging of this lesion, the hard palate was intact with thin bone remaining between the maxillary sinus floor.

Surgical treatment involved wide local excision of the tumor including the capsule and surrounding periosteum and complete curettage of the underlying bone. Reconstruction of the defect depends on the remaining anatomy and structural support, as well as the desired long-term outcome. A removable prosthesis such as an obturator or surgical stent can be used during the healing process. After adequate soft tissue healing is accomplished, further surgeries such as bone or soft tissue grafts can be performed to obtain a more final

prosthetic foundation.

The recurrence rate is low following surgical excision. If recurrence occurs, it is likely due to inappropriate surgical techniques. Leaving soft tissue involved with the lesion can cause microscopic extensions or cells to seed surrounding tissue. Therefore, wide surgical excision is necessary. Following surgical removal, long-term follow-up is recommended despite the low rate of recurrence.

CONCLUSION

Pleomorphic adenomas of the anterior hard palate are seen infrequently as most will be found in the parotid gland. The most common findings associated with this lesion are a painless, slow-growing mass. Computed Tomography is beneficial in the diagnostic process. However, histopathological studies remain the standard for definitive diagnosis. Radiographic imaging through CT scans to aid in determining bony involvement and relative margins. Current treatment modalities include surgical excision with curettage of bone and overlying periosteum. When significant bony defects are present, reconstruction can be performed through various means including bone grafts, removable prosthetics, or implantable hardware. Long-term follow-up is encouraged, although recurrence is uncommon following surgical excision.

References:

1. Brannon, R. *The odontogenic keratocyst. Oral Surgery, Oral Medicine, Oral Pathology*, 1976; 42(10):54 – 72)

2. Neville, B. W., Damm, D., Allen, C., Chi, A., (2016). *Oral and maxillofacial pathology*. Saint Louis: Elsevier.

3. Marx, R. E., & Stern, D. (2012). *Oral and maxillofacial pathology: A rationale for diagnosis*

and treatment. Chicago: Quintessence Publ

4. Miloro, M., & Peterson, L. J. (2012). *Peterson's principles of oral and maxillofacial surgery*. Shelton, CT: Peoples Medical Pub. House-USA

5. Patigaroo SA(1), Khan NA(1), Kirmani MH(1), etal. *Pleomorphic Adenoma of Hard Palate: An Experience. Journal of Maxillofacial and Oral Surgery*. 13(1):36-41. doi:10.1007/s12663-012-0448-5.

6. Satpathy Y, Spadigam AE, Dhupar A, Syed S. *Epithelial and stromal patterns of pleomorphic adenoma of minor salivary glands: A histopathological and histochemical study. Journal of Oral & Maxillofacial Pathology (0973029X)*. 2014;18(3):379

NEW DIGITAL WORKFLOW FOR TREATING COMPLEX BALLISTIC INJURIES

OF THE MAXILLOFACIAL REGION; COMBINING COMMERCIALY AVAILABLE VIRTUAL SURGICAL PLANNING WITH IN-HOUSE 3D PRINTING: A case report

James Pledger, DDS
 Jeffrey Brooks, DMD
 Brett Wilson, DDS
 Christopher Holladay, DMD
 Daniel Townsend, DDS

INTRODUCTION

Facial trauma is a key component of the practice of oral and maxillofacial surgery. Due to the increased suicide ideation¹ and suicide rates in the United States over the past decade², self-inflicted gunshot wounds (SIGSWs) are common in suicide attempts with 4,799 SIGSWs to the head or facial area reported in 2021³. Therefore, management of these injuries will continue to be critical for the oral and maxillofacial surgeon. Fortunately, new technologies, specifically computer-based surgical planning tools, are helping redefine how complex facial injuries such as SIGSWs are managed⁴⁻⁶.

In this report, we present a complex pan-facial injury resulting from a SIGSW to the face in an alleged suicide attempt. This injury was successfully treated with staged open reconstruction employing commercially available Stryker Virtual Surgical Planning (VSP) and in-house 3D printed bio-models to allow pre-bending of the titanium reconstruction plate for an optimal surgical outcome.

CASE REPORT

A 27-year-old Caucasian female presented to the Regional One Health (ROH) level one trauma center in Memphis, Tennessee, following a self-inflicted gunshot wound to the submental area with a nasal dorsum exit wound. The patient was intubated upon arrival at ROH. An initial clinical exam revealed a ballistic injury to the face resulting in complex facial fractures and lacerations to the tongue, face, and oral cavity. A computed tomography (CT)

ABSTRACT

The presented report describes the treatment of a 27-year-old Caucasian female who presented to Regional One Health level one trauma center in Memphis, Tennessee, with a self-inflicted, high-velocity ballistic injury to the face. Clinical diagnoses based on computed tomography and clinical examination revealed complex hard and soft tissue injuries to the mandible and maxilla. Virtual surgical planning was performed to reduce the facial fractures and produce a stereolithographic file that was used to print a mandibular model and occlusal splint. A stock titanium reconstruction plate was bent using the in-house 1:1 bio-model and was found to fit intraoperatively with the same precision that it fit the 1:1 bio-model. Staged treatment included irrigation and debridement with the closure of complex soft tissue lacerations and extraction of indicated teeth followed by open reduction of the mandibular fractures and placement of 3D printed occlusal splint. A second staged procedure utilizing an outsourced VSP model provided by Stryker 3D Systems allowed ORIF of the Le Fort II fracture and ORIF of bilateral nasal-orbital-ethmoid fractures after placement of the patient into a maxillomandibular fixation. The patient's continued postoperative care was coordinated with an outside OMFS provider in her home state; therefore, no final imaging is available. This case demonstrates the ability to have virtual planning performed by a third party, yet all 3-dimensional printing is accomplished in-house. While VSP and bio-models are routinely utilized in maxillofacial surgery, it is typically all performed by one entity. This case is unique as it demonstrates the ability to have VSP performed by a third party but having all models and splints printed in-house by the surgeon.

scan of the maxillofacial area was obtained (Fig 1.) which demonstrated a Le Fort II fracture, palatal fractures, bilateral nasal-orbital-ethmoid fractures, bilateral mandibular body, and symphysis fractures, and avulsed teeth #5, 6, and 25.

After a careful diagnostic exam of the facial injuries, a comprehensive treatment plan was developed. Total repair in a single surgery was not appropriate for this case. The staged treatment of choice began with irrigation and debridement with the closure of complex soft tissue lacerations and extraction of indicated teeth by OMFS

following tracheostomy performed by general surgery.

Due to the complexity of the maxillary and mandibular fractures, virtual surgical planning was performed with the Stryker 3D Systems (Fig 2.). The fabrication and delivery of the models can take up to 4 days. The patient required more timely intervention and an STL file of the simulated reconstructed model was sent directly from 3D Systems.

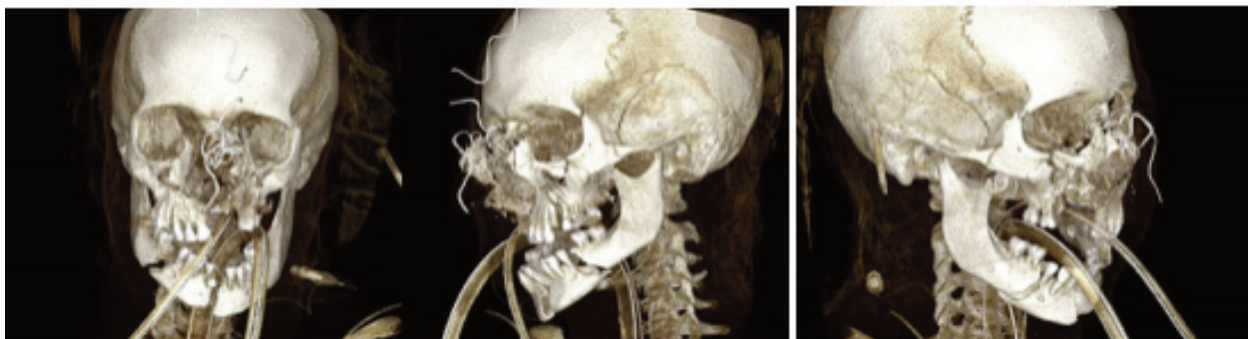

Figure 1: 3D reconstruction of initial CT

This file was used to print a 1:1 bio-model and occlusal splint at the University of Tennessee College of Dentistry Oral and Maxillofacial Surgery department. The printer used was an Envisiontec, Vector 3SP enterprise-scale production 3D printer. A stock Biomet reconstruction plate was pre-bent using the 3D bio-model in the OMFS clinic. This was all performed within 24 hours of completing the VSP.

The patient was taken to the operating room for repair of the mandibular, palatal, and dentoalveolar fractures. The Stryker virtual surgical plan, occlusal splint, and pre-bent titanium reconstruction plate fit the intraoperative bony defects with the same precision as the bio-models printed in the OMFS clinic. Postoperative CT scans were obtained which demonstrated excellent position and contour of the hardware (Fig 3.).

The patient tolerated the procedure well with an uneventful immediate postoperative course. The patient's midface was later reconstructed using the same Stryker 3D Systems medical modeling days after completion of the mandibular plating. Before discharge to another hospital system in their home state, the patient developed an anterior supra-platysmal infection at the ballistic entrance wound. This was successfully treated with irrigation and debridement followed by systemic antibiotic treatment. The patient was maintained in maxillomandibular fixation for 6 weeks. Imaging for the case only encompasses the procedures completed by the OMFS team while at ROH. Other imaging after discharge with any further reconstruction was unable to be obtained.

DISCUSSION

Virtual surgical planning has repeatedly demonstrated its usefulness in the treatment of maxillofacial trauma⁴⁶ by improving anatomic reduction while reducing cost and operating room time⁷¹. Prolonged operating time has been shown to increase surgical complications¹². A meta-analysis by Cheng et al. (2018) found a 14% increase in the likelihood of complications for every 30 minutes of additional surgical time, therefore reducing operating time is critical to optimizing surgical outcomes.

Comprehensive virtual surgical planning of similar complex fracture patterns typically involves custom plate fabrication and model printing, necessitating time delay from surgical planning to delivery of fabricated custom reconstruction plates. This also delays case completion while increasing patient length of stay. In this case, the time was virtually eliminated by printing the VSP-generated bio-models and splints in-house and pre-bending the reconstruction plates. Time is a critical component in optimizing the treatment of complex facial fractures, and by eliminating the waiting period, the patient was able to begin reconstructive surgery promptly.

Virtually planning the surgical outcome with Stryker 3D Systems utilizing the individual anatomical measurements of the patient and using the digital files to print out a 1:1 scaled bio-model in the OMFS clinical setting enabled the surgical team to optimize surgical time and outcome. As seen in the post-operative CT imaging (Fig 3.), the pre-bent titanium reconstruction bar fits exceptionally well to the mandible once the fractures were reduced. This replicated the adaptation of the reconstruction plate on the printed bio-model.

VSP has demonstrated its merits for maxillofacial surgery, but it is important to appreciate its limitations. Fully guided VSP cases take time. Reasons that delay VSP from data collection to operative theatre include the multidisciplinary approach, delays associated with the manufacture and delivery of products, and human error⁴. One way to mitigate time limitations associated with VSP is to utilize in-house components when feasible instead of commercially available VSP products. There is no significant difference in surgical outcome between using commercially available VSP and in-house VSP¹³. Software is available to surgeons that allow the creation and manipulation of virtual models specific to patients essentially mimicking commercially available products such as 3D Systems. However, these programs require a high level of technical understanding as well as surgical expertise to provide accurate models. This tends to be too time-consuming for the surgeon and therefore continues to be performed by bioengineers employed by these planning services. 3D printing has become widely popular and is less technique sensitive compared to the creation of virtual models. As mentioned before, the planning and fabrication of commercial models are accurate but time-consuming and often prohibit their use in the setting of trauma. Therefore, a hybrid of commercially available VSP combined with in-house 3D printing can optimize surgical planning and negate the time of delay for the delivery of products. This case report demonstrates the digital workflow available to surgeons who are proficient at 3D printing. However, this hybrid model allows prompt surgical intervention while still maintaining excellent accuracy.

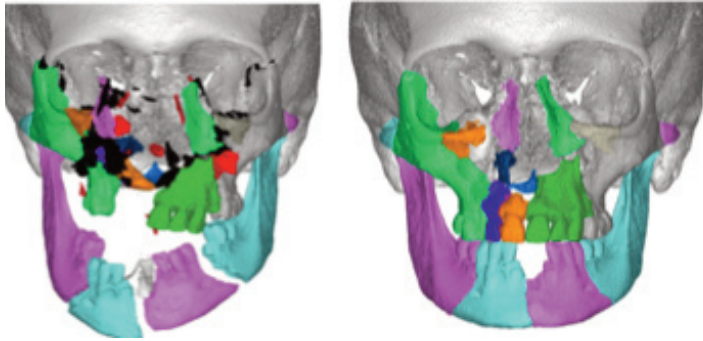


Figure 2: Virtual surgical planning (pre-op and simulated post-operative) with Stryker 3D Systems

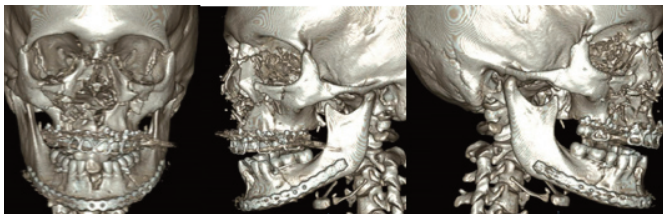


Figure 3: 3D reconstruction of post-operative ORIF of mandible fractures, reduction of palatal and alveolar fractures with an occlusal splint

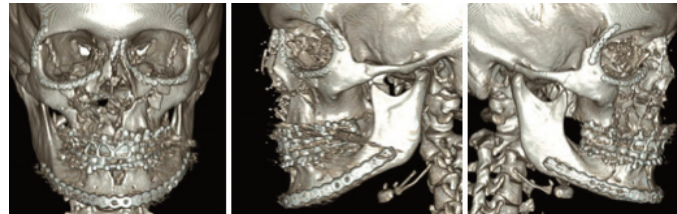


Figure 4: 3D reconstruction of post-operative ORIF of the Le Fort II fracture and bilateral nasal-ethmoid-orbital fractures

References:

- Dubé, J. P., Smith, M. M., Sherry, S. B., Hewitt, P. L., & Stewart, S. H. (2021). Suicide behaviors during the COVID-19 pandemic: A meta-analysis of 54 studies. *Psychiatry Research*, 301, 113998. <https://doi.org.ezproxy.uthsc.edu/10.1016/j.psychres.2021.113998>
- Centers for Disease Control and Prevention, National Center for Health Statistics. Underlying Cause of Death 1999-2020 on CDC WONDER Online Database, released in 2021. Data are from the Multiple Cause of Death Files, 1999-2020, as compiled from data provided by the 57 vital statistics jurisdictions through the Vital Statistics Cooperative Program. Accessed at <http://wonder.cdc.gov/ucd-icd10.html>
- Faith Quenzer, Andrew Givner, Rachel Dirks, Christopher J. Coyne, Frank Ercoli, & Ricard Townsend. (2021). Self-Inflicted Gun Shot Wounds: A Retrospective, Observational Study of U.S. Trauma Centers. *Western Journal of Emergency Medicine*, 22(3). <https://doi.org.ezproxy.uthsc.edu/10.5811/westjem.2021.4.49315>
- Hua, J., Aziz, S., & Shum, J. W. (2019). Virtual Surgical Planning in Oral and Maxillofacial Surgery. *Oral and Maxillofacial Surgery Clinics of North America*, 31(4), 519-530. <https://doi.org.ezproxy.uthsc.edu/10.1016/j.coms.2019.07.011>
- Hua, J., Aziz, S., & Shum, J. W. (2019). Virtual Surgical Planning in Oral and Maxillofacial Surgery. *Oral and Maxillofacial Surgery Clinics of North America*, 31(4), 519-530. <https://doi.org.ezproxy.uthsc.edu/10.1016/j.coms.2019.07.011>
- Thakker, J. S., Pace, M., Lowe, I., Jung, P., & Herford, A. S. (2019). Virtual Surgical Planning in Maxillofacial Trauma. *Atlas of the Oral & Maxillofacial Surgery Clinics of North America*, 27(2), 143-155. <https://doi.org.ezproxy.uthsc.edu/10.1016/j.cxom.2019.05.006>
- Voss, J. O., Varjas, V., Raguse, J.-D., Thieme, N., Richards, R. G., & Kamer, L. (2016). Computed tomography-based virtual fracture reduction techniques in mandibular fractures. *Journal of Cranio-Maxillo-Facial Surgery*, 44(2), 177-185. <https://doi.org.ezproxy.uthsc.edu/10.1016/j.jcms.2015.11.010>
- Azarmehr, I., Stokbro, K., Bell, R. B., & Thygesen, T. (2017). Surgical Navigation: A Systematic Review of Indications, Treatments, and Outcomes in Oral and Maxillofacial Surgery. *Journal of Oral and Maxillofacial Surgery*, 75(9), 1987-2005. <https://doi.org.ezproxy.uthsc.edu/10.1016/j.joms.2017.01.004>
- Barr, M. L. (1), Rezzadeh, K. S. (1), Lee, J. C. (1), Pfaff, M. J. (1), Haveles, C. S. (2), Castro, R. (2), Nolan, I. T. (3), & Steinbacher, D. (4). (n.d.). Virtual Surgical Planning for Mandibular Reconstruction with the Fibula Free Flap: A Systematic Review and Meta-analysis. *Annals of Plastic Surgery*, 84(1), 117-122. <https://doi.org.ezproxy.uthsc.edu/10.1097/SAP.0000000000002006>
- Dell, A. O. G., Abbate, V., Maglillo, F., Bonavolontà, P., Salzano, G., Romano, A., Reccia, A., Committeri, U., laconetta, G., & Califano, L. (2018). Low-cost, self-made CAD/CAM-guiding system for mandibular reconstruction. *Surgical Oncology*, 27(2), 200-207. <https://doi.org.ezproxy.uthsc.edu/10.1016/j.suronc.2018.03.007>
- Resnick, C. M., Inverso, G., Wrzosek, M., Padwa, B. L., Kaban, L. B., & Peacock, Z. S. (2016). Is There a Difference in Cost Between Standard and Virtual Surgical Planning for Orthognathic Surgery? *Journal of Oral and Maxillofacial Surgery*, 74(9), 1827-1833. <https://doi.org.ezproxy.uthsc.edu/10.1016/j.joms.2016.03.035>
- Shakya, S., Li, K.-D., Huang, D., Liu, Z.-Q., Zhang, X., & Liu, L. (2021). Virtual surgical planning is a useful tool in the surgical management of mandibular condylar fractures. *Chinese Journal of Traumatology*. <https://doi.org.ezproxy.uthsc.edu/10.1016/j.cjtee.2021.12.002>
- Cheng, H., Clymer, J. W., Po-Han Chen, B., Sadeghirad, B., Ferko, N. C., Cameron, C. G., & Hinoul, P. (2018). Prolonged operative duration is associated with complications: a systematic review and meta-analysis. *Journal of Surgical Research*, 229, 134-144. <https://doi.org.ezproxy.uthsc.edu/10.1016/j.jss.2018.03.022>
- Johal, M., Ma, J. N. B., Parthasarathi, K., Dunn, M., Howes, D., Wallace, C., Palme, C. E., Leinkram, D., Cheng, K., & Clark, J. R. (2021). Institutional-based and commercial virtual surgical planning in maxillomandibular reconstruction – Comparing the digital plan and postoperative scan. *Journal of Plastic, Reconstructive & Aesthetic Surgery*. <https://doi.org.ezproxy.uthsc.edu/10.1016/j.bjps.2021.11.075>

CLASSIFIEDS

PRACTICE FOR SALE

Practices for Sale

Choice Transitions currently has several practices for sale. From smaller/starter practices ideal for more recent grads all the way to large, multi-doctor practices! Our inventory is constantly changing as practices sell and new practices are listed. To investigate these opportunities please visit and register for FREE on our website at www.choicetransitions.com or Contact Fred Bacon, DDS at (877) 365-6786, x220 or Jay Lowrey at x221

Savannah: Incredible opportunity. Six (6) operatories in resort community. Equipped with digital x-ray and an intra-oral scanner. Contact Don McMillan, 615-499-9058, donald.mcmillan@henryschein.com. #TN2861

*Memphis Area: 3 Op periodontal practice. Dexis sensors, Digital pano, and updated equipment. 40 years goodwill. Revenue over \$900K. Seller will stay 6-12 mo. For details contact Charles Russell, mark.russell@henryschein.com, 504.655.2364. #TN2865

*Selmer: Established practice with gross collections 2021 - \$917,000. Digital office with 4 equipped ops and room to expand. Real Estate available in near future. Owner willing to help through transition. For details contact Steve Murphree: steve.murphree@henryschein.com, 256.227.5811. #TN2882

*Selmer: Established practice with gross collections 2021 - \$917,000. Digital office with 4 equipped ops and room to expand. Real Estate available in near future. Owner willing to help through transition. For details contact Steve Murphree: steve.murphree@henryschein.com, 256.227.5811. #TN2882

Nashville Suburb: High production practice near Nashville boasting 1.5 million in collections. This 8 operator fully digital practice is setup in the heart of a rapidly expanding population with no competition. For details contact, Scott Owen, scott.owen@henryschein.com, 678.780.5394. #TN2995

*Maryville, TN: Rare opportunity with this 3,000 sq. ft. stand-alone office. With 4 operatories, this digital/paperless practice is completely turnkey. Collections over \$1.2 million. Don't miss out. Email or call for private showing: Lindsey Ingram, lindsey.ingram@henryschein.com, 919.316.8537 or 800.988.5674. #TN3002

*Nashville: Excellent smaller practice 15 mins from downtown in this location 30 years. Two operatories, nicely equipped, room for one additional. Digital. Great opportunity for a start-up with 600 patients. For details contact Steve Murphree: steve.murphree@henryschein.com, 256.227.5811. #TN3092

*Bristol: 6 ops +room to expand. Unique location draws from 3 states. Features digital x-rays, CEREC, separate lab and sterilization areas. Room to grow with minimal competition nearby. For details contact Lindsey Ingram, lindsey.ingram@henryschein.com, 919.316.8537 or 800.988.5674. #TN-315

*Western TN: Great opportunity to own a well-established general practice. 6 equipped operatories and \$704,000 in collections in 2021. For details contact Scott Owen, scott.owen@henryschein.com, 678.780.5394. #TN3171

*Memphis: Own two practices in one office! Centrally located, collecting a combined total of \$1,335,500 in 2021. Mostly PPO patients, Eaglesoft, over 2,500 sqft, and 6 operatories in a high-traffic main commercial thoroughfare with parking. Contact Charles Russell, mark.russell@henryschein.com, 504.655.2364. #TN3204

*Memphis: Own two practices in one office! Centrally located, collecting a combined total of \$1,335,500 in 2021. Mostly PPO patients, Eaglesoft, over 2,500 sqft, and 6 operatories in a high-traffic main commercial thoroughfare with parking. Contact Charles Russell, mark.russell@henryschein.com, 504.655.2364. #TN3205

Classified Advertising (Ad Prepayment Required)

Classified ads: The first 100 characters (i.e., letters, spaces, punctuation) are free* for TDA dentist members and \$40.00 for nonmembers. Each character, in excess of 100, is an additional 40 cents per character (this applies to members and nonmembers).

Mail checks made payable to the TDA, along with your typed or clearly printed classified ad, by the 1st of the month prior to the month of publication to: TDA Newsletter, 660 Bakers Bridge Avenue, Suite 300, Franklin, TN 37067.

TDA reserves the right to reject any advertising. Call the TDA Executive Office at 615-0628-0208 or email tda@tndentalassociation.org if you have any questions.

* Free to TDA members: one ad per year — three (3) month maximum — after third month the \$40.00 minimum and additional character charge will apply.

*Parsons: Established, six (6) operatory crown and bridge /restorative practice with 3 hygienists. Fully digital office with 6 employees. Smaller town with very loyal patient base. Collections average \$570,000 per year. For details contact Steve Murphree: steve.murphree@henryschein.com, 256.227.5811. #TN3228

Practice for Sale:

Knoxville, 4 ops, collections around \$420k with after debt service income over \$135k.

Great practice for new or recent grad. Contact Wiley Carr 423-902-5396 wcarr@paragon.us.com

EQUIPMENT FOR SALE

Intraoral X-Ray Sensor Repair/Sales We repair broken sensors. Save thousands in replacement costs. Specializing in Kodak/Carestream, major brands. We buy/sell sensors. American SensorTech 919-229-0483 www.repairsensor.com

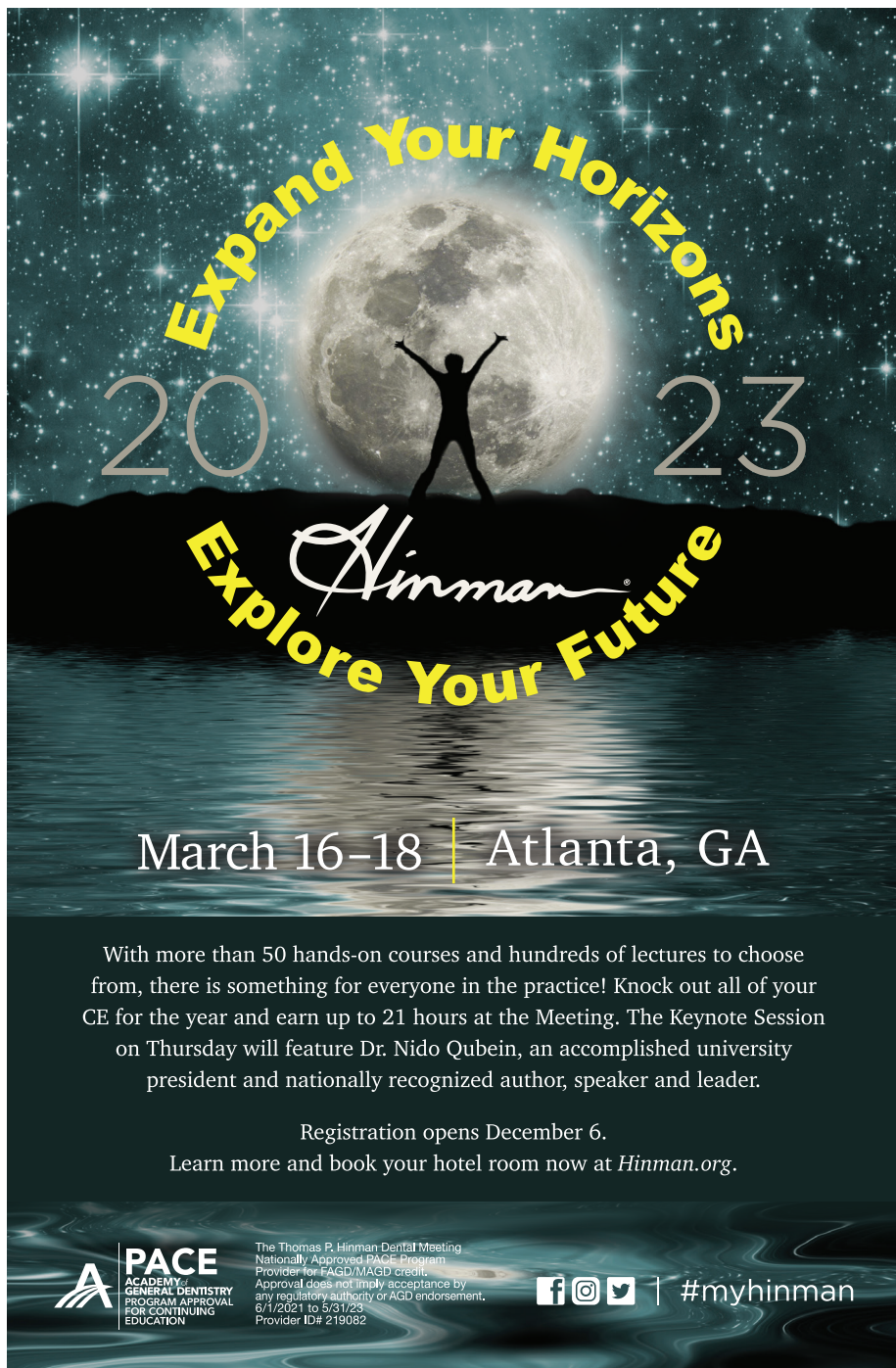
CAREER OPPORTUNITIES

General Dentist Needed

Have you considered working for a great dental group and making at least \$175,000 part time or at least \$300,000 full time? We are looking for highly committed and skilled dentists to match our busy fee for service practice. We offer the most updated technology for comprehensive diagnosing. Schedules are flexible with available evening and weekend hours in an updated, technology-driven practice. Contact Jared @ 402-714-6647 our Recruiting Coordinator.

Pediatric Dentist Needed, West, TN

Full or Part time. Top earnings potential to join a 45-year old Pediatric Dentistry practice. Large draw area and strong new patient flow. Every Thursday is a short work day. No Fridays. Short work days during the summer. Path to partnership available. 401k, Signing bonus.



Expand Your Horizons

2023


Explore Your Future

Hinman




March 16-18 | Atlanta, GA

With more than 50 hands-on courses and hundreds of lectures to choose from, there is something for everyone in the practice! Knock out all of your CE for the year and earn up to 21 hours at the Meeting. The Keynote Session on Thursday will feature Dr. Nido Qubein, an accomplished university president and nationally recognized author, speaker and leader.

Registration opens December 6.
Learn more and book your hotel room now at Hinman.org.

 **PACE**
ACADEMY
GENERAL DENTISTRY
PROGRAM APPROVAL
FOR CONTINUING
EDUCATION

The Thomas P. Hinman Dental Meeting
Nationally Approved PACE Program
Provider for FAGD/MAGD credit.
Approval does not imply acceptance by
any regulatory authority or AGD endorsement.
6/1/2021 to 5/31/23
Provider ID# 219082

   | #myhinman